



The Effects of Alkaloids Fraction of *Cyperus esculentus* on Some Biochemical Parameters and Histopathology of the Testis of Lead-Induced Toxicity

**Godson Emeka Anyanwu^a, Luqman Adepoju Hassan^a,
Ifeanacho Ezeteonu Abireh^{b*} and Nto Johnson Nto^a**

^a University of Nigeria, Nsukka, Enugu State, Nigeria.

^b Enugu State University of Science and Technology, Enugu, Nigeria.

Authors' contributions

This work was carried out in collaboration among all authors. All authors read and approved the final manuscript.

Article Information

DOI: 10.9734/JPRI/2021/v33i50A33382

Editor(s):

(1) Dr. Sachin Kumar Jain, IPS Academy College of Pharmacy, India.

Reviewers:

(1) Dennis Amaechi, Veritas University, Nigeria.

(2) Farah Saeed, Dow University of Health Sciences, Pakistan.

Complete Peer review History: <https://www.sdiarticle4.com/review-history/76060>

Original Research Article

Received 02 September 2021

Accepted 09 November 2021

Published 15 November 2021

ABSTRACT

Aim: This study evaluated the protective effect of alkaloids fraction of *Cyperus esculentus* on lead-induced testicular toxicity in Wistar rat.

Methodology: Twenty-five adult male Wistar rats were randomly divided into five (5) groups, (n=5). Group 1 was administered with 1ml normal saline only, group 2 was administered with 30 mg/kg of lead, group 3 was administered with 50mg/kg of alkaloids and 30 mg/kg of lead, group 4 was administered with 100 mg/kg of alkaloids and 30 mg/kg of lead, group 5 was administered 150mg/kg of alkaloids and 30 mg/kg of lead orally for 28 days. The testes of the rats were harvested on day 29 of the experiment and histological studies done using the H&E and Verhoeff-Van Gieson (VVG) stains. Sperm parameters, sex hormones and antioxidant of testicular homogenates were analysed.

Results: Histological examination of the testes revealed increased spermatogenic cells and Leydig cell proliferation in the rats in groups 3, 4, and 5 administered with 50 mg/kg, 100 mg/kg, and 150 mg/kg of Alkaloids, and 30 mg/kg of lead, respectively, when compared with group 2 administered with 30 mg/kg of lead alone. Also there was significant increase in levels of serum testosterone ($p <$

*Corresponding author: E-mail: ifeanachoabireh@gmail.com;

.05) in groups 3, 4, and 5 when compared with group 2. There was increase in levels of follicle stimulating hormone in groups 4, and 5 when compared with group 2. However, significant decreased in luteinizing hormone was observed in groups 3, 4 and 5. Group 2, treated with 30 mg/kg of lead only showed increased malondialdehyde levels when compared with group 1 that received 1ml normal saline. Group 3, 4, and 5, treated with 50 mg/kg, 100 mg/kg, and 150 mg/kg of alkaloid plus 30 mg/kg lead, respectively, showed significant growth of seminiferous epithelium, improved sperm quality, and decreased levels of malondialdehyde ($p < .05$).

Conclusion: This study shows that alkaloids fraction of *Cyperus esculentus* may have a protective effect on the testis of Wistar rat when it is exposed to toxicity from lead.

Keywords: Alkaloids; *Cyperus esculentus*; lead; testis; spermatogenesis; leydig cell.

1. INTRODUCTION

Lead is a common environmental toxic metal that induces several physiological, histological, behavioural, and biochemical abnormalities in humans and animals [1]. Lead toxicity remains a common problem in both developing and industrialized countries due to unavoidable environmental and occupational exposure [2]. The mechanism of lead toxicity involves induction of oxidative stress [3]. The mechanism of lead-induced oxidative stress involves an imbalance between generation and removal of reactive oxygen species (ROS) in tissues and cellular components causing damage to membranes, DNA and proteins [4]. Lead has been reported to cause oxidative stress by generating the release of reactive oxygen species (ROS) such as superoxide radicals, hydrogen peroxide and hydroxyl radicals and lipid peroxides [5]. Lead acetate enhances lipid peroxidation and nitric oxide production in both serum and testes with concomitant reduction in antioxidant enzymes as catalase and superoxide dismutase [6]. Oxidative stress has a pathological role in the degeneration of tissue in the body [3].

Many plants have been screened for their medicinal properties [7], and these plant products such as fruits and vegetables are important source of balance diet and nourishment [8]. The use of plant in the treatment of disease provides a less expensive and safer therapy [9,10]. *Cyperus esculentus* tuber (Tigernut) known as 'Aki awusa' and 'Aya' by the Igbo and Hausa tribes of Nigeria, respectively, is consumed in Nigeria for its aphrodisiac and fertility potentials [10], and it has been observed to have protective effect against flutamide-induced testicular damage [10].

The phytochemicals in *Cyperus esculentus* include alkaloids, tannins, saponnins, phenols, steroids, glycosides, and terpenoids [11]. Thus

this study was designed to study the protective role of alkaloids fractions on lead-induced testicular toxicity in Wistar rat.

2. MATERIALS AND METHODS

2.1 Chemicals and Reagents

The Lead acetate used for this study was obtained from Sigma-Aldrich (Loius, MO, USA), while Oxidative stress markers assay kits were procured from Elabscience (Houston, TX, USA). The other drugs and routine laboratory reagents used were purchased from registered distributors in Enugu metropolis.

2.2 Extraction of Alkaloids from Tiger Nuts

Cyperus esculentus (tigernut) was procured at Ogbete Market, Enugu, Enugu State, Nigeria. The tuber was identified and authenticated at the Botany department, University of Nigeria, Nsukka, Enugu State. Fresh *Cyperus esculentus* were weighed and air-dried under room temperature. It was then grinded into powder form using grinding machine. The powdered material was sieved to remove the ungrounded fibres. All fats and oil were removed from the sample using *n*-hexane [12]. The alkaloid was then extracted with ethanol solvent. The extraction was done multiple times to make sure all the alkaloids get isolated. Rotary evaporator EV400 Touch manufactured by Clarkson Laboratory and Supply Inc, China was used to evaporate the solvent. Two drops of Mayer's reagent were added along the sides of test tube into 20g of the isolate. And a white creamy precipitate indicated the isolate was alkaloids [13].

2.3 Experimental Animals and Design

Twenty-five (25) male Wistar rats with mean weight of 120g were purchased from the animal house of Department of Anatomy, University of

Nigeria, Enugu Campus. The rats were housed in netted cages and fed with grower's mash, and allowed two weeks for acclimatization. They were kept under standard laboratory conditions, with temperature at 25°C, humidity of 60-70% and they had 12-hour light and dark cycles throughout the experiment. The Wistar rats were divided randomly into five groups, 1-5 (n=5). Group 1 (negative control) was administered with 1ml normal saline orally throughout the twenty-eight (28) days of the experiment. Group 2 was administered with 30mg/kg of lead orally, daily for twenty-eight (28) days. Group 3 was administered with 50mg/kg of alkaloids orally, plus 30mg/kg of lead orally, for the twenty-eight (28) days period of the experiment. Group 4 was administered with 100mg/kg of alkaloids orally, plus 30mg/kg of lead, orally, for twenty-eight days. Group 5 was administered with 150mg/kg of alkaloids orally, plus 30mg/kg of lead orally, for twenty-eight days.

2.4 Sample Collection

After 24 hours following the administration of the last dose (day 29) blood samples were collected from all the groups by aid of capillary tube via retro-orbital puncture, and kept in non-heparinised vacutainer for analysis.

Animals in all groups were anesthetized with intraperitoneal thiopentone 50mg/kg. The pelvis of each rat was opened up through the midline lower abdominal incision to exposed the testes. The testes were immediately removed and trimmed off fat, weighed, and then kept in Bouin's fluid until histological and histochemical analysis [14].

2.5 Specimen Analysis

Spermatozoa from the epididymis were put into 2ml of Hams F10 medium containing 0.5% bovine serum albumin [15]. After 5 minutes of incubation at 37°C with 5% CO₂, the epididymis sperm reserves were determined using a hemocytometer. Sperm motility was analyzed with a light microscope (Leica DM750) and reported as the mean number of motile sperm according to the method developed by the World Health Organization [16].

The blood in the non-heparinized vacutainer bottle was spun at 2500rpm for 10min using a bio-centrifuge (MSE, O-5122A, Germany). The level of free serum testosterone, luteinizing hormone and follicle stimulating hormone in the

serum was measured with ECOBAS-6000 hormone analyzing machine.

Lipid peroxidation products were estimated by measuring TBARS as described by Niehaus and colleagues [17]. The non-enzymatic antioxidants, glutathione (GSH) and catalase (CAT), were estimated using the method described by Ellman [18]. Superoxide dismutase activity in the testis was determined according to the method described by Marklund and colleague [19].

The testis was fixed and analyzed using routine histological technique. The paraffin sections were cut 3-µm thick and stained with hematoxylin and eosin (H and E) and Verhoeff-Van Gieson (VVG) stain, and studied using light microscope.

2.6 Statistical Analysis

Statistical differences between the groups were evaluated using one-way ANOVA, followed by Dunnett's comparison test to compare between the treated and control groups. p value of 0.05 or less was considered statistically significant.

3. RESULTS

3.1 Testes and Body Weight

There was significant ($p < 0.05$) increase in the body weight of group 2 treated with 30mg/kg lead alone when compared to that of group 1 that received 1ml normal saline. Groups 3, 4, and 5 that were given 50mg/kg, 100mg/kg, and 150mg/kg of alkaloid, respectively, plus lead 30mg/kg had a significant ($p < 0.05$) increase in body weight when compared to group 1. There was significant ($p < 0.05$) decrease in testicular weight of rats in group 2 when compared with group 1. However, the groups that were treated with graded doses of alkaloid (groups 3, 4, and 5) had a significant increase in testicular weight when compared to the group 2 that was treated with lead 30mg/kg alone. This is shown in Table 1.

3.2 Sperm Analysis

As shown in Table 2, Lead treatment significantly decreased sperm count, motility, and viability in the group treated with lead 30 mg/kg (group 2) when compared with group 1, that was given 1 ml normal saline, and other experimental groups (groups 3, 4, and 5). Groups 3, 4 and 5 had significant ($p < 0.05$) increase in sperm count when compared to group 2. The sperm motility

was also observed to have significant increase in groups 3, 4, and 5, that received 50 mg/kg, 100mg/kg, and 150mg/kg of alkaloid in addition to 30mg/kg of lead, when compared with group 2 that received 30 mg/kg of lead alone.

3.3 Result of Hormonal Assay

Groups 3, 4 and 5 that received alkaloid at 50mg/kg, 100mg/kg, and 150mg/kg, respectively, in addition to lead at 30mg/kg had significant increase in the levels of serum testosterone with $p < 0.05$ when compared with group 2, treated with 30mg/kg of lead alone. However, when compared with group 1 that received normal saline, the levels of testosterone in groups 3, 4, and 5 were observed to have significant decreased level ($p < 0.05$). There was also significant increase in level of follicle stimulating hormone in groups 4 and 5 ($p < 0.001$) when compared with group 2. Significant decreased in

luteinizing hormone was observed in groups 2, 3, 4 and 5 when compared with group 1. This is as shown in Table 3

3.4 Result of Oxidative Markers

As shown in Table 4, the study observed significant ($p < 0.05$) decrease in the levels of SOD, CAT, GSH in group 2 treated with 30mg/kg of lead alone when compared to the control (group 1) treated with 1ml normal saline. But significant ($p < 0.05$) increase in the level of MDA was observed in group 2 treated with 30mg/kg lead only when compared with group 1. There was significant increase ($p < 0.05$) in the levels of SOD, CAT, and MDA in groups 3, 4, and 5 treated with 50mg/kg, 100mg/kg, and 150mg/kg of alkaloid, respectively, in addition to 30mg/kg of lead when compared with group 2. However, there was no significant increase in level of GSH in groups 3, 4, and 5.

Table 1. The Effects of Alkaloid and lead on body weight and testicular weight

Groups	Initial Body Weight (g)	Final Body Weight (g)	Testicular weight (g)
1	144.20±0.86	245.53±0.40 (41.3%)	1.66±.05
2	112.83±0.57	241.13±0.57 (53.2%)	1.29±.05 ^a
3	85.06±0.57	208.86±0.57 (59%)	1.35±.05
4	106.16±0.57	198.93±0.57 (47%)	1.45±.05 ^b
5	72.83±0.57	221.96±1.15 (67.2%)	1.45±.05 ^b

Table 2. The Effects of Alkaloid and Lead on Sperm parameters.

Groups	Sperm count (x10 ⁶)	Sluggish (%)	Non-Motile (%)	Active (%)
1	190.33±.57	19.66±.57	15.0±.00	65.33±.58
2	80.33±.57 ^a	0.00±.00 ^a	100.00±.00 ^a	0.03±.05 ^a
3	120.33±.57 ^{a,b}	15.10±.11 ^{a,b}	25.10±.23 ^{a,b}	30.03±.05 ^{a,b}
4	120.33±.57 ^{a,b}	25.00±.17 ^{a,b}	55.13±.00 ^{a,b,c,d}	50.06±11 ^{a,b,c}
5	150.33±.57 ^{a,b}	15.13±.00 ^a	15.00±.05 ^a	60.03±.05 ^{a,b}

Table 3. Showing the result of hormonal assay

Groups	Testosterone	Follicle stimulating hormone	Luteinizing hormone
1	5.04±.00	0.80±.00	8.20±.00
2	2.04±.00 ^a	0.30±.00	7.70±.00
3	3.02±.00 ^a	0.20±.00	7.10±.00
4	3.10±.00 ^a	0.60±.00	6.30±.00
5	3.10±.00 ^a	0.60±.00	6.30±.00

Table 4. Effects of Alkaloid and lead on Oxidative stress Makers

Groups	SOD (U/mg)	CAT(U/mg)	MDA (nmol/mg)	GSH (nmol/mg)
1	26.10±.00	13.30±.00	0.52±.00	2.30±.00
2	12.60±.00a	8.30±.00a	3.40±.00a	1.10±.00a
3	21.30±.00b	16.00±.00b	1.10±.00b	1.40±.00
4	28.50±.00 b	12.30±.00b	1.20±.00b	1.90±.00
5	28.50±.00 b	12.30±.00b	1.20±.00b	1.90±.00

3.5 Result of Histological Analysis of the Testis

Sections of the seminiferous tubules of group 1 that received normal saline had circular or oval outlines with normal stratified seminiferous tubule epithelium showing cells of the spermatogenic series and spermatozoa within the lumen as shown in Fig. 1a. The basement membrane of the seminiferous tubule is intact and the interstitium and Leydig cells are well preserved as shown in Fig. 2a. The seminiferous tubules of the rats in group 2, treated with Lead at 30mg/kg alone showed severe reduction of cells of the spermatogenic series, hypocellularity in the interstitium, widening of the tubular lumen, tubular atrophy, and fewer spermatozoa in the tubular lumen as shown in Figs. 1b and 2b. Also there is thickened and irregular basement

membrane of the seminiferous tubule (Fig. 2b). The seminiferous tubules of the rats in group 3, treated with 50mg/kg of alkaloid plus 30mg/kg of lead, showed increased number of cells of the spermatogenic series (Fig. 1c), but the basement membrane was still distorted (Fig. 2c) when compared with group 1 (Figs. 1a and 1b). As observed in Fig. 1d and 2d, the animals treated with 100mg/kg of alkaloid plus 30mg/kg of lead (group 4) had seminiferous tubules and Leydig cells that are similar to that of group 1. Figs. 1d, 2d, 1e and 2e (groups 4, and 5) show increased cellular components of the seminiferous tubules when compared to Fig.1b and 2b (group 2). These groups (groups 4, and 5) also showed cells of the spermatogenic series and normal cellular composition in their germinal epithelium with sperm cells in the lumen and a normal interstitium.

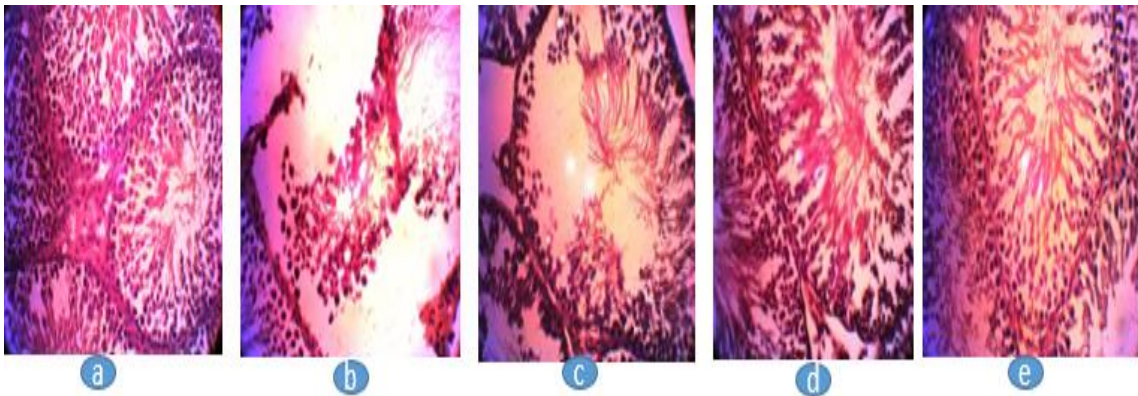


Fig. 1. Photomicrograph of testis (x200), stained with Haematoxylin and Eosin, showing the interstitium, Leydig cells, seminiferous tubule, and spermatogenic series. All of various sizes and shapes and numbers. Severe distortion of the seminiferous tubule is observed in '1b'

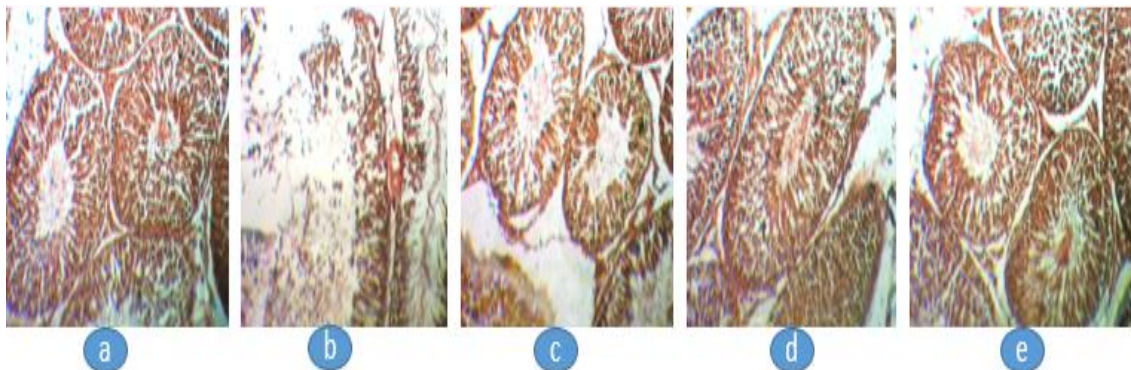


Fig. 2. Photomicrograph of testis (x200), stained with Verhoeff-Van Gieson (VVG) stain, showing the interstitium, Leydig cells, seminiferous tubule, and spermatogenic series. All of various sizes and shapes and numbers. Thickened irregular basement membrane in addition to degenerated spermatogenic epithelium was observed in '2b'

4. DISCUSSION

Since time immemorial man has used various parts of plants in the treatment and prevention of many diseases, including impotence [20]. Ancient people knew about herbal and animal aphrodisiacs used in combinations like portions to treat infertility, increase sexual performance, desire and pleasure [21]. Herbal medicine are alternative medications prepared from plants and plant extracts used to treat illnesses and Ailments [22]. Herbal medicine is obtained from a wide variety of natural sources including plant leaves, bark, flowers, and roots [23]. Alkaloids has been reported to have antioxidant property [24]. This study observed that Lead administration decreased the relative weights of the testis and the body weight of the experimental animals. Lead administration caused significant reduction in sperm count, motility, and viability by subjecting the spermatozoa to increased oxidative stress-induced damage, due to plasma membranes containing large quantities of polyunsaturated fatty acids and their cytoplasm containing low concentrations of scavenging enzymes [25,26]. Increased formation of reactive oxygen species has been correlated with decreased sperm motility [27].

The link between reactive oxygen species and reduced sperm motility may be due to a cascade of events that result in rapid loss of intracellular adenosine triphosphate leading to axonemal damage and sperm immobilization [25,28]. This study also observed that exposure to Lead caused a decrease in testosterone concentration, indicating interference with steroidogenesis. Administration of alkaloids fraction of *Cyperus esculentus* increased testosterone levels, and indicated the protective effect of alkaloids fraction of *Cyperus esculentus*. This effect relates to the induction of oxidative stress. The result of this study showed that GSH, CAT, and SOD activities were distinctly lower in the testis of lead-exposed rat. Therefore, the increase in malondialdehyde (MDA), a by-product of lipid peroxidation, observed in this study might be due to the concomitant increase in the generation of free radicals such as OH and H₂O₂ in the testis of the lead-exposed rat [26,29]. In this study, alkaloids increased testicular antioxidant enzymes and decreased MDA levels. Alkaloids fraction of *Cyperus esculentus* also prevented the ravaging effects of Lead on sperm parameters and testicular antioxidant enzymes. *Cyperus esculentus* (Tigernut) contains

significant amounts of antioxidants [10]. Therefore, it is reasonable to infer that the antioxidant constituents of alkaloids boosted the testicular non-enzymatic and enzymatic antioxidants to effectively scavenge free radicals and therefore prevent lipid peroxidation. This is also reflected in the increased sperm count and motility.

This study showed histological abnormalities in the testicular tissue of rats given lead alone, such as shortening of the seminiferous epithelium, which led to decreased counts of cells of the spermatogenic series. Lead has been observed to cause the sloughing of germ cells in the seminiferous tubules and increases in histological lesions in the seminiferous tubules and epithelial lining of the testes with absence of Sertoli cells [30]. Testosterone produced in the interstitial cells of Leydig is necessary for the maintenance of established spermatogenesis [31]. The reduced cellularity of the interstitium in the testes of the rats treated with Lead alone might have produced the decrease in testosterone and consequently poor spermatogenesis observed in this study. Alkaloids fraction of *Cyperus esculentus* maintained the histoarchitecture of the testis, increased the proliferative activity of spermatogonia, and maintained cells of the spermatogenic series. Thus the findings of this study shows that alkaloids protected the testis from the harmful effects of Lead.

5. CONCLUSION

Alkaloids fraction of *Cyperus esculentus* effectively lowered Lead-induced oxidative stress by reducing MDA levels, and ameliorated the deleterious effects of Lead on serum testosterone levels and Follicle stimulating hormone. Alkaloids fraction of *Cyperus esculentus* also promoted germinal epithelial growth and protected the cytoarchitecture of the testis from the damaging effects of Lead. The antioxidant properties of the Alkaloids fraction of *Cyperus esculentus* may be responsible for its protective effect on testis against Lead-induced testicular toxicity.

DISCLAIMER

The products used for this research are commonly and predominantly use products in our area of research and country. There is absolutely no conflict of interest between the authors and producers of the products because we do not

intend to use these products as an avenue for any litigation but for the advancement of knowledge. Also, the research was not funded by the producing company rather it was funded by personal efforts of the authors.

CONSENT

It is not applicable.

ETHICAL APPROVAL

Ethical clearance for this study was obtained from The Ethical Committee, Faculty of Basic Medical Sciences, University of Nigeria, Enugu Campus.

COMPETING INTERESTS

Authors have declared that no competing interests exist.

REFERENCES

1. El-Tantawy WH. Antioxidant Effects of Spirulina Supplement Against Lead acetate-induced Hepatic Injury in Rats. *J. Tradit. Complement. Med.* 2016; 6: 327–331.
2. Abdel-Zaher AO, Abd-Ellatief RB, Aboulhagag NA, Farghaly HSM, Al-Wasei FMM. The Interrelationship Between Gasotransmitters and Lead-induced Renal Toxicity in Rats. *Toxicol. Lett.* 2019; 310:39–50.
3. Flora G, Gupta D, Tiwari A. Toxicity of Lead: A Review with Recent Updates. *Interdiscip. Toxicol.* 2012; 5: 47–58.
4. Patra RC, Swarup D, Dwivedi SK. Antioxidant Effects of α tocopherol, Ascorbic Acid and L-methionine on Lead-induced Oxidative Stress to the Liver, Kidney and Brain in Rats. *Toxicology.* 2001; 162(2):81-88.
5. E-Nekeety AA, El-Kady AA, Soliman MS, Hassan NS, Abdel-Wahhab MA. Protective Effect of *Aquilegia vulgaris* (L.) Against Lead Acetate-induced Oxidative Stress in Rats. *Food Chem Toxicol.* 2009; 47: 2209–2215.
6. Abdel-Moniem AE, Dkhil MA, Al-Quraishy S. Protective Role of Flaxseed Oil Against Lead Acetate Induced Oxidative Stress in Testes of Adult Rats. *Afr J Biotechnol.* 2010;9(42): 7216–7223.
7. Tamunotonye W, Jacks SA, Asala JP. Testicular Enhancement Activity of Aqueous Extract of *Pausinystalis macroceras* Stem Bark in Wistar Rats. *J Anat Sci.* 2007;1(1):3-6.
8. Ibrahim TA, Jude BS, Giwa EO, and Adebote VT. Rea search *Journal of Agric and Biological Sciences*, 2009; 5(6): 1143-1145.
9. Ezugworie JO, Akpobasaha S, Nto NJ, Finbarrs-Bello E, Agu AU and Esom EA. The Histological and Hormonal Effect of Aqueous Extract of the Bark of *Boswellia dalzielii* on the Testis of Male Wistar Rat, *Int. J. Pure App. Biosci.* 2018; 6(2): 31-36.
10. Hassan LA, Anyanwu GE, Nto JN, Abireh IE, Akunna GG. Protective Effect of Aqueous Extract of *Cyperus esculentus* on Flutamide-induced Testicular Defect of Male Wistar Rats. *Scholar Journal of Applied Medical Sciences*, 2018; 6(6): 2391-2395.
11. Ekeanyanwu RC, Njoku O, Ononogbu IC. The Phytochemical Composition and Some Biochemical Effect of *Cyperusesculentus*. *Pakistan Journal of Nutrition.* 2010; 9(7):709-715.
12. Soni B, Visavadiya NP, Madamwar D. *Toxicology.* 2008, 248(1): 59-65.
13. Yanli H, Li G, Xiaohong J, et al. *Food Science.* 2007;28(1):12-14.
14. Awwiuro OG. *Histology and Tissue Pathology. Principles and Techniques.* 2nd ed. Ibadan: Claverianum Press; 2010.
15. Feng R, He W, Ochi H. A New Murine Oxidative Stress Model Associated With Senescence. *Mech Ageing Dev.* 2001; 122:547-59.
16. World Health Organization (2010). WHO laboratory manual for the Examination of Human Semen and Sperm Cervical Mucus Interaction. 5th edition. WHO Cambridge University press. 5:332-345.
17. Niehaus WG, Samuelsson B. Formation of Malonaldehyde from Phospholipid Arachidonate During Microsomal Lipid Peroxidation. *Eur J Biochem.* 1968; 6:126-130.
18. Ellman GL. Tissue Sulphydryl Groups. *Arch Biochem Biophys.* 1959; 82:70-77.
19. Marklund S, Marklund G. Involvement of the Superoxide Anion Radical in the Autoxidation of Pyrogallol and a Convenient Assay for Superoxide Dismutase. *Eur J Biochem.* 1974; 47:469-74.
20. Ayyanar M and Ignacimuthu S. Herbal Medicines for Wound Healing Among Tribal People in Southern India:

- Ethnobotanical and Scientific Evidences. International Journal of Applied Research in Natural Products. 2009; 2(3):29-42.
21. Malviya NE, Jain SA, Gupta VB, Vyas S. Recent Studies on Aphrodisiac Herbs for the Management of Male Sexual Dysfunction-a review. Acta Pol Pharm. 2011; 68(1):3-8.
 22. Burke A, Smyth A, FitzGerald GA. Analgesic Antipyretic Agents. In: Goodman LS, Gilman A, Brunton LL, eds. The Pharmacological Basis of Therapeutics. 11th ed. New York: McGraw-Hill; 2006; p. 637-731
 23. Khaki A, Fathiazad F, Nouri M, Khaki AA, Ghanbari Z, Ghanbari M, Ouladsahebmadarek E, Javadi L, Farzadi L. Antioxidative Effects of Citro Flavonoids on Spermatogenesis in Rat. Afr J Pharm Pharmacol. 2011; 5:721-5.
 24. Speiky H, Bruce KC, Eduardo AL, Luis AV. Antioxidant Properties of the Alkaloid Boldine in Systems Undergoing Lipid Peroxidation and Enzyme Inactivation. Biochemical Pharmacology. 1991; 41(11), 1575-1581.
 25. Bansal AK, Bilaspuri GS. Impacts of Oxidative Stress and Antioxidants on Semen Functions. Vet Med Int. 2010;5: 1-7.
 26. Saleh RA, Agarwal A, Kandirali E, Sharma RK. Leukocytospermia is Associated with Increased Reactive Oxygen Species Production by Human Spermatozoa. Journal of Fertility and Sterility. 2002; 78: 1215 -1224.
 27. Armstrong JS, Rajasekaran M, Chamulitrat W, Gatti P, Hellstrom WJ, Sikka SC. Characterization of Reactive Oxygen Species Induced Effects on Human Spermatozoa Movement and Energy Metabolism. Free Rad Biol Med. 1999; 26:869-80.
 28. de Lamirande E, Gagnon C. Impact of Reactive Oxygen Species on Spermatozoa: a Balancing Act Between Beneficial and Detrimental Effects. Hum Reprod. 1995; 10:15-21.
 29. Dosumu O, Onunkwor B, Odukoya O, Arowolo T, Ademuyiwa O. Biomarkers of Lead Exposure in Auto-mechanics in Abeokuta, Nigeria. Trace Elem. Electrolyte. 2005; 22(3): 185-191.
 30. Chowdhury AR. Recent Advances in Heavy Metals Induced Effect on Male Reproductive Function: a retrospective. Almeen J. Med. Sci. 2009; 2:37-42
 31. Zirkin BR. Spermatogenesis: its Regulation by Testosterone and FSH. Semin Cell Dev Biol. 1998; 9:417-21.

© 2021 Anyanwu et al.; This is an Open Access article distributed under the terms of the Creative Commons Attribution License (<http://creativecommons.org/licenses/by/4.0>), which permits unrestricted use, distribution, and reproduction in any medium, provided the original work is properly cited.

Peer-review history:

The peer review history for this paper can be accessed here:
<https://www.sdiarticle4.com/review-history/76060>