

# Adrenal Myelolipoma: A Rare Case Report and Review of Literature

Houssame Lachhab <sup>a\*</sup>, Mehdi Safi-Eddine <sup>a</sup>,  
Amine Moataz <sup>a</sup>, Mohamed Dakir <sup>a</sup>,  
Adil Debbagh <sup>a</sup> and Rachid Aboutaieb <sup>a</sup>

<sup>a</sup> Urology Department, Ibn Rochd University Hospital, Casablanca, Morocco.

## **Authors' contributions**

*This work was carried out in collaboration among all authors. All authors read and approved the final manuscript.*

## **Article Information**

### **Open Peer Review History:**

This journal follows the Advanced Open Peer Review policy. Identity of the Reviewers, Editor(s) and additional Reviewers, peer review comments, different versions of the manuscript, comments of the editors, etc are available here: <https://www.sdiarticle5.com/review-history/99063>

## **Case Study**

**Received: 15/02/2023**

**Accepted: 18/04/2023**

**Published: 25/04/2023**

## **ABSTRACT**

Adrenal myelolipoma is a rare benign tumor originating from the adrenal cortex. Composed of adipose tissue and bone marrow. The incidence of adrenal myelolipoma is 0.08 to 0.2% of autopsy cases and 0.06% of patients operated. Large tumors of a size greater than 7 cm should be removed. We report here the case of a 41 years old patient with a large right adrenal myelolipoma. The radiological outcomes and surgical management.

**Keywords:** Adrenal; myelolipoma; benign; mass; abdominal MRI.

## **1. INTRODUCTION**

“Adrenal myelolipoma is a rare benign tumor composed of variable proportions of adipose tissue and bone marrow represented by all three lineages of hematopoietic elements” [1]. “The

pathogenesis of myelolipoma is obscure, usually asymptomatic and generally has a diameter <5 cm” [2]. Its imaging characteristics are so specific that the radiological diagnosis can be certain [3]. Large tumors require surgical treatment [3].

\*Corresponding author: Email: [lachhabhoussame@gmail.com](mailto:lachhabhoussame@gmail.com);

## 2. CASE PRESENTATION

A 41 years old male patient, chronic active smoker, presented with chronic right lower back pain for two years, without hematuria, neither lower urinary tract disorders or associated digestive symptoms. The whole evolving in a context of apyrexia and conservation of the general status.

On clinical examination, the patient was conscious 15/15, with normal blood pressure 120/70 mmHg, normal heart rate 72 bpm and apyretic. The urogenital examination showed tenderness in the right lumbar fossa.

On the paraclinical level, an uro-TDM was performed showing a rounded mass on the adrenal space, with regular contours, fat density

(-90 HU), with thin septa, measuring 98x95x94 mm (Fig. 1). An abdominal MRI was performed in addition, showing an oval right adrenal mass, in T1 and T2 hypersignal, cancelling in FAT SAT without any sign of loco-regional invasion (Fig. 2). This radiographic appearance was in favor of an adrenal myelolipoma. The biological examination was without abnormalities.

Given the tumor size and the painful symptomatology of the tumor mass, surgical exploration by thoraco-phreno-laparotomy was performed. The exploration showed a large right retroperitoneal mass without signs of invasion of adjacent organs. A tumorectomy was performed without incident. The postoperative course was simple. The histopathological examination was in favor of an adrenal myelolipoma.

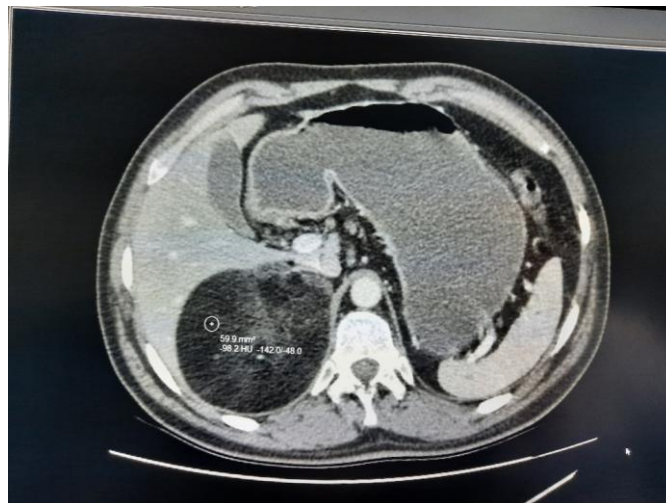


Fig. 1. Uro-TDM showing the mass

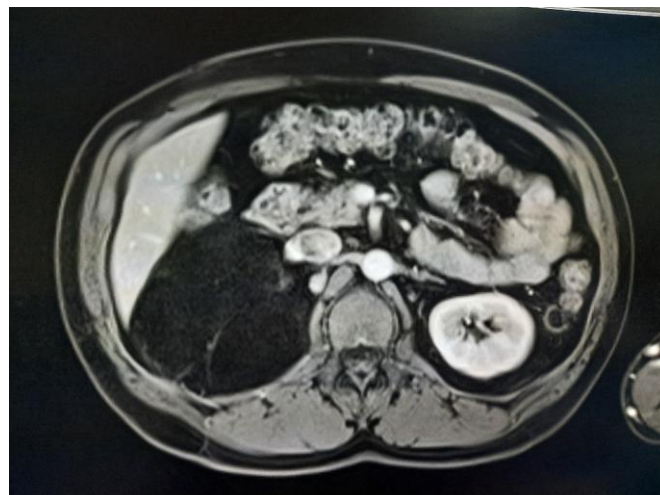


Fig. 2. MRI with oval right adrenal mass

### 3. DISCUSSION

“Adrenal myelolipoma is a rare benign tumor originating from the adrenal cortex and is usually nonfunctional” [1]. This neoplasm is composed of variable proportions of adipose tissue and bone marrow represented by all three lineages of hematopoietic elements.

“The incidence of adrenal myelolipoma is 0.08 to 0.2% of autopsy cases and 0.06% of patients operated. The average age of onset is 54 years with a slight male predominance. It is most often unilateral and right-sided, however, bilateral forms have been described” [2].

“The pathogenesis of myelolipoma is obscure. It is hypothesized that the primary event is a metaplastic change occurring in the reticuloendothelial cells of the blood capillaries due to stimuli like necrosis, infection or stress. Another major group of hypotheses relates to hormonal pathways (adrenocorticotropin hormone)” [3].

Adrenal myelolipoma is usually asymptomatic and generally has a diameter <5 cm, discovered either during an autopsy or, more often, during radiological investigations for other conditions. A high blood pressure may be observed in the case of compression of a renal artery [2].

“A small percentage of patients presents with abdominal symptoms, flank pain or haematuria. Even life-threatening haemorrhagic shock has been described in myelolipomas larger than 10 cm. The symptoms appear to be caused by mechanical compression or tumour necrosis or retroperitoneal haemorrhage” [4,5].

Its imaging characteristics are so specific that the radiological diagnosis can be certain. The echography shows a heterogeneous lesion with a hyperechoic aspect corresponding to the fatty contingent. The computed tomography shows a mass with regular contours, with two components: the mature adipose tissue spontaneously hypodense (< 30 HU), and hematopoietic marrow cells (30-50 HU), heterogeneously enhancing [6,7]. “On magnetic resonance imaging, the appearance of the tumor demonstrates the high signal intensity and reduced signal intensity depending on the T1-weighted or T2-weighted sequences, respectively. Retroperitoneal fat-containing tumors like teratoma, lipoma, myolipoma,

angiomyolipoma, and liposarcoma may mimic AML radiologically” [1].

“Small tumours should be managed by annual radiological screening in an outpatient setting. Large tumors of a size greater than 7 cm should be removed, as they carry a potential risk of malignancy and retroperitoneal haemorrhage due to spontaneous rupture” [8,9].

Symptomatic tumors or with hormonal activity should also be removed by laparotomy or laparoscopy. Laparoscopic adrenalectomy is safe and effective [3] “Larger tumors require greater exposure, and it may be necessary to make large incisions such as Chevron (bilateral subcostal) or thoracoabdominal incisions as our case. Good exposure is crucial to avoid damaging the vena cava on the right or the aorta on the left, among other structures. The fact that myelolipomas are encapsulated allows them to be easily separated from the surrounding structures” [10,11].

### 4. CONCLUSION

Adrenal myelolipoma is a benign and nonsecretory tumor that is often discovered incidentally. Its size can vary from a few millimeters to tens of centimeters; it can compress neighboring organs, becoming symptomatic. The preoperative diagnosis can be established by medical imaging to avoid unnecessary surgery in small asymptomatic tumors. In other cases, a surgical removal is necessary to demonstrate benignity.

### CONSENT

As per international standard or university standard, parental(s) written consent has been collected and preserved by the author(s).

### ETHICAL APPROVAL

As per international standard or university standard written ethical approval has been collected and preserved by the author(s).

### COMPETING INTERESTS

Authors have declared that no competing interests exist.

## REFERENCES

1. Adapa S, Naramala S, Gayam V, Gavini F, Dhingra H, Hazard FKG, et al. Adrenal Incidentaloma: Challenges in Diagnosing Adrenal Myelolipoma. J Investig Med High Impact Case Rep. Déc 2019;7:2324709619870311.
2. Arrami A, Mahi M, Amil T, El Fenni J, Saouab R. Myélolipome surrenalien. J Imag Diagn Interv. 2018;1(4):237-8.
3. Decmann Á, Perge P, Tóth M, Igaz P. Adrenal myelolipoma: a comprehensive review. Endocrine. 2018;59(1):7-15.
4. Zorgdrager M, Pol R, Hemel B van, Ginkel R van. Giant adrenal myelolipoma: when trauma and oncology collide. Case Rep. 2014;2014:bcr2014204023.
5. Masson E. Tumeurs non sécrétantes de la surrenale et incidentalome. EM-Consulte. [cité 28 avr 2022]. Available: <https://www.em-consulte.com/article/44792/tumeurs-non-secretantes-de-la-surrenale-et-incident>
6. Al-Bahri S, Tariq A, Lowentritt B, Nasrallah DV. Giant bilateral adrenal myelolipoma with congenital adrenal hyperplasia. Case Rep Surg. 2014;2014:728198.
7. Daneshmand S, Quek ML. Adrenal myelolipoma: diagnosis and management. Urol J. 2006;3(2):71-4.
8. Baisakh MR, Chatteraj A, Narayanan R, Mohanty R, Mishra M. Adrenal myelolipoma: A rare lesion of adrenal gland. Indian J Cancer. 2015;52(4):597-8
9. Littrell LA, Carter JM, Broski SM, Wenger DE. Extra-adrenal myelolipoma and extramedullary hematopoiesis: Imaging features of two similar benign fat-containing presacral masses that may mimic liposarcoma. Eur J Radiol. 2017;93:185-194
10. Wadood DQ, Qureshi DSA, Singh DP, Freedman DJ. A rare case of co-existing adrenal and pelvic myelolipomas. Radiol Case Rep. 2018;13(5):999-100
11. Bokhari, Maria R., Hassam Zulfiqar, and Vishnu V. Garla. Adrenal Myelolipoma. Stat Pearls. Stat Pearls Publishing; 2022.

© 2023 Lachhab et al.; This is an Open Access article distributed under the terms of the Creative Commons Attribution License (<http://creativecommons.org/licenses/by/4.0>), which permits unrestricted use, distribution, and reproduction in any medium, provided the original work is properly cited.

*Peer-review history:*

*The peer review history for this paper can be accessed here:*

*<https://www.sdiarticle5.com/review-history/99063>*