



## **D-trans-allethrins in Some Selected Mosquito Coil Repellents Causes Histological Inflammation in Trachea of Experimental Animals**

**A. Abdulaziz<sup>1</sup>, O. G. Avwioro<sup>2</sup>, M. O. Abdul Rasheed<sup>3</sup>, M. S. Abubakar<sup>4</sup>,  
U. Abubakar<sup>3\*</sup>, S. D. Abubakar<sup>5</sup> and M. B. Shagari<sup>1</sup>**

<sup>1</sup>Department of Histopathology, Usmanu Danfodiyo University Teaching Hospital, Sokoto, Nigeria.

<sup>2</sup>Department of Anatomy, Delta State University, Delta State, Nigeria.

<sup>3</sup>Department of Histopathology, School of Medical Laboratory Science, Usmanu Danfodiyo University, Sokoto, Nigeria.

<sup>4</sup>Department of Histopathology, Faculty of Veterinary Medicine, Usmanu Danfodiyo University, Sokoto, Nigeria.

<sup>5</sup>Department of Medical Laboratory Science, Ahmadu Bello University, Zaria, Kaduna State, Nigeria.

### **Authors' contributions**

*This work was carried out in collaboration among all authors. Author AA carried out the work and drafted the manuscript. Author OGA overall supervisor and scrutinizer of the work approved the final manuscript. Author MOAR interpreted the histology slides and references arrangement. Author MSA designed the work and managed the work. Author UA handle and take care of the animal for extract administration and sacrifice. Author SDA carried out statistical analysis. Author MBS carried out literature review search. All authors read and approved the final manuscript.*

### **Article Information**

DOI: 10.9734/IJPR/2019/v3i3330096

Editor(s):

(1) Dr. Khadiga Ahmed Ismail Eltris, Professor, Faculty of Medicine, Ain Shams University, Cairo, Egypt.

Reviewers:

(1) Umezurike Benedict Chidozie, Nigeria.

(2) Muhammad Muizz Uddin, Dow University of Health Sciences, Pakistan.

Complete Peer review History: <http://www.sdiarticle4.com/review-history/53554>

**Original Research Article**

**Received 01 November 2019**

**Accepted 03 January 2020**

**Published 10 February 2020**

### **ABSTRACT**

**Background:** Many reports on the toxicity of some mosquito repellents have been recorded, however, its effect on the trachea.

**Aim:** This study was aimed at determining the Histopathological and Morphological changes in Trachea of Wistar rats exposed to selected mosquito repellents commonly used in Sokoto, Nigeria especially after the recent outbreak of Malaria and Dengue fever.

**Methods:** Mosquito repellent brands of Pyrethroids-containing mosquito coil, aerosolized spray and Dichlovors aerosolized spray were studied over 21 days. Rats were exposed to the fumes in coils and aerosolized insecticidal spray for 5 minutes each day, in a well-ventilated box. Control rats were not exposed. Animals were sacrificed on days 7, 14 and 21 post-exposure.

**Results:** Early observable behavioural signs include irritation, scratching of the eyes and nostrils; in later stages of exposure, sneezing, ruffled fur and lethargy were observed. Gross changes were not apparent in most organs, except for frothy trachea observed in few Wistar rats exposed to the fumes. Histopathology revealed varying degrees of epithelial disruption, lymphocytic infiltration and vascular congestion; more apparent 7 days post-exposure and to a lesser degree, 21 days post-exposure. The severity of the macroscopic changes was more in the first 14 days of exposure while it was reduced in rats that were exposed for 21 days. The most obvious changes were observed in coil repellents containing Rich-d-Trans allethrin.

**Conclusion:** Acute exposure to fumes of mosquito repellents containing rich-d-trans allethrin is irritating to the trachea and could lead to possible respiratory problems.

*Keywords: Mosquito repellents; trachea, wistar rats; allethrin; respiratory pathology.*

## 1. INTRODUCTION

In Nigeria, many families have used mosquito repellents both coil and sprays as their primary source of prevention of mosquito-borne diseases because they are cheap, easily accessible and relatively effective.

Respiratory diseases are associated with many factors that may include exposure to the harmful agent to the respiratory system. The respiratory system is that system in the body that is responsible for the conduct, humidification, and alteration of air temperature and exchange of Gases. It is divided into the Conducting (Nose, Nasopharynx, Larynx, Trachea, Bronchi and Bronchioles) and Exchange unit (respiratory bronchioles, Alveolar Duct, Alveolar Sac and Alveoli) [1]. Malaria is one of the most widely spread health hazards in the tropics and the subtropical regions. It is one of the major public health problems in Nigeria, contributing to a quarter of the malaria burden in Africa. The vast majority of cases occur in children and pregnant women [2]. Children are especially vulnerable, accounting for more than two-thirds of global malaria deaths. Malaria in pregnancy can lead to maternal mortality, anaemia and low birth weight, a major cause of infant mortality [3].

Many tools and treatments have been put in place to achieve the elimination of malaria in many African countries, Nigeria inclusive. These types of intervention which include the use of insecticide (Mosquito Repellents) have been proven to be insufficient because the malaria parasite has developed resistance to currently available insecticides and drugs. Some forms of mosquito coils have been shown to have a toxic effect on the lungs of female rats Okine et al. [4].

Animal studies with long-time exposure to mosquito coil show abnormal skin cell, poor weight gain and lung damage [5]. Hepatic, renal and haematological changes have been reported Thatheyus et al. [6], Ayorinde et al. [7], damage on the respiratory organs however, were not fully defined.

Describing the active ingredients more significant in morphological and histological changes will be essential in the future planning of health care policies and for education to the teeming resource-poor masses in Nigeria and other resource-poor countries.

## 2. MATERIALS AND METHODS

### 2.1 Study Location

The study was conducted at the Department of Histopathology, School of Medical Laboratory Science, Usmanu Danfodiyo University, Sokoto, Nigeria.

### 2.2 Experimental Animals

Adult Wistar rats (100-120 g) were procured from the animal house of the Ahmadu Bello University, Zaria, Nigeria. They were kept in a well-ventilated room with optimum environmental conditions of temperature, relative humidity, dark/light cycle and were fed standard feed pellets and tap water *ad libitum*. They were allowed to acclimatize for two (2) weeks and observed for any ailment that may render them unfit for the experiment.

### 2.3 Procurement of Mosquito Repellents

The mosquito repellents employed in this study were purchased from the commercial store at

Diplomat area, Sokoto, Nigeria. The mosquito repellents employed were selected using a simple random sampling technique. The coil forms were Wave tide (Hangzhou Jiadehao Commodity Co.Ltd.) and Baoma (Fujian Benma Daily Chemical Limited). Each coil is 70 cm long, weighs 12 g and contains 0.2% w/w composition of d-Allethrin, and Rich-d-Trans allethrin as active ingredient respectively. The spray foam included Rambo (Gongoni Company Limited, Nigeria) contains 0.25% Transfluthrin and 0.20% Permethrin active ingredient (all synthetic pyrethrin) in a 300 ml pressurized liquid canister and Sharp-Sharp (Onitsha Company, Nigeria) containing 70% Dichlorvos active ingredient.

## 2.4 Experimental Design

45 Adult Wistar rats (Male and Female) were randomly grouped into five groups. The groups were as follows; Group A-Control with 9 Wistar rats, Groups- B, C, D and E. [ Wave tide (Coil 1), Baoma (Coil 2), Rambo (Spray 1) and Sharp (Spray 2)] respectively, each of which contains 9 Wistar rats. The Wistar rats in the coil groups B and C were exposed to 10 g/kg of the coil for 5 minutes once a day for 21 days. While dose in the spray groups D and group E were exposed to 0.45 ml/kg for 5 minutes once a day for 21 days.

Boxes measuring 53.5 cm x 39.5 cm were demarcated with wire mesh to allow a small space for the mosquito coil which was in a separate compartment from the rats to prevent the rats from knocking over the coil and starting a fire while allowing the smoke to penetrate and saturate the box for maximum exposure of the rats to the fumes. Several holes were made on the boxes to allow for proper ventilation. Fumes Several holes were made on the boxes to allow for proper ventilation.

The rats in each group were observed for any observable behavioural signs associated with the exposure to the active ingredient from the fumes. The rats were sacrificed using the method of cervical dislocation and dissected to obtain the tracheas for morphological and histopathological studies. Briefly, tracheas were rinsed in normal saline and fixed in 10% normal saline. Paraffin-embedded tissue sections were stained by H&E and observed microscopically.

## 2.5 Data Analysis

All the results obtained were expressed as mean  $\pm$  Standard Error of mean. Data analysis was

performed using SPSS (Version 20) software. Gross and histopathological scoring were subjected to Kruskal-Wallis H Test. While data on body weight were subjected to two-way ANOVA. A value of  $p < 0.05$  was considered to be statistically significant.

## 3. RESULTS

### 3.1 Behavioural Observation

The behavioural signs observed in this study include; irritation of the eyes and nostrils, scratching of nostrils and closing of the eyes. The rats exposed to both coils and sprays exhibited these signs. In the later stages (14-21 days), sneezing, gurgling, ruffled fur and lethargy were observed. From 11 days onwards, the rats started exhibiting some adaptive mechanisms by clustering at an end of the box away from the fumes, while others were observed to be placing their nose on the tiny hole of the box to avoid inhalation of the fumes.

### 3.2 Use of Any of the Repellents did not Affect Weight Changes

The effect of selected mosquito repellent on the Weight of Wistar rats is represented in Table 1. Wistar rats exposed to the different types of selected mosquito repellents showed no significant difference in body weight with a  $p$ -value greater than 0.05.

### 3.3 Allethrins Induce Observable Macroscopic Changes in Lungs of Wistar Rats

Table 2 shows the mean rank for gross change scores of tracheas. Control group have the lowest score when compared with fume exposed groups. The gross change scoring of Wistar rats exposed for 21 days exhibited no significant differences among groups as  $p$ -value is greater than 0.05. However, the group exposed to Baoma fumes has the highest mean rank. The morphological changes were highest at 7 days and reduced till 21 days. The changes compared to the other groups even at 21 days was remarkable.

### 3.4 Acute Exposure to Allethrins Induce Tracheal Inflammation in Wistar Rats

Several inflammatory processes were observed prominently in rats exposed to Baoma throughout the study, more prominent is the epithelial disruptions seen in Table 3. There were slight

**Table 1. Comparison of body weight of Wistar rats pre-and post-exposure to selected mosquito repellents**

Duration of exposure	A(Control) N=3	B(Wavetide) N=3	C(Baoma) N=3	D(Rambo) N=3	E(Sharp) N=3
<b>7 days</b>					
Pre-exposure	141.67±6.36	161.00±6.66	153.00±14.11	156.00±11.02	139.33±13.17
Post-exposure	158.67±12.13	144.67±7.54	132.33±3.18	158.00±9.71	131.33±7.22
<b>14 days</b>					
Pre-exposure	138.00±15.54	155.00±7.09	178.33±15.72	174.33±1.77	162.33±5.49
Post-exposure	104.00±52.21 <sup>a</sup>	160.33±6.84	179.67±14.66	177.33±1.45	162.00±4.16
<b>21 days</b>					
Pre-exposure	162.33±14.24	148.00±16.17	155.67±0.88	174.33±9.33	181.33±12.44
Post-exposure	119.33±59.67	152.00±18.08	162.67±2.91	181.33±10.81	188.00±11.79

**Table 2. Gross changes of trachea 7 days, 14 days and 21 days post-exposure to selected mosquito repellents**

Group	Gross change (Frothy trachea)		
	7 days	14 days	21 days
A(Control)	7.00	6.50	7.50
B(Wavetide)	7.00	9.00	7.50
C(Baoma)	12.00 <sup>a</sup>	11.50 <sup>a</sup>	10.00 <sup>a</sup>
D(Rambo)	7.00	6.50	7.50
E(Sharp)	7.00	6.50	7.50
P-Value	0.71	0.183	0.406

Mean rank having different superscript in the same column are significantly different ( $p \leq 0.05$ ) (Kruskal Wallis comparison test)

**Table 3. Histological changes in trachea 7 days post-exposure to selected mosquito repellents**

Group	Change scores (Mean rank)		
	Epithelial disruption	Lymphocytic infiltration	Vascular congestion
A(Control)	6.00	5.50	5.50
B(Wavetide)	6.00	10.17 <sup>c</sup>	5.50
C(Baoma)	13.33 <sup>b</sup>	11.00 <sup>c</sup>	10.83 <sup>c</sup>
D(Rambo)	6.00	5.50	10.83 <sup>c</sup>
E(Sharp)	8.67	7.83	7.33
P-Value	0.037	0.221	0.176

Mean rank having different superscript in the same column are significantly different ( $p \leq 0.05$ ) (Kruskal Wallis comparison test)

reductions as the study progressed. Lymphocytic infiltration was seen in rats exposed to Wavetide and vascular congestion was observed in rats exposed to Rambo.

### 3.5 Histological Changes in Trachea 14 Days Post-exposure to Selected Mosquito Repellents Persistent Tracheal Inflammation in Allethrin-exposed Wistar Rats

Table 4 shows that a comparison of the control group with the lowest mean rank and fume exposed group exhibited significant differences among groups in epithelial changes 14days post-exposure having the highest mean rank and a p-

value of 0.037. Effects were marked in rats exposed to allethrins via a coil. The coil containing pure allethrin showed more inflammatory features while those exposed to rich-d-trans allethrin showed less inflammatory cells but worse features overall.

### 3.6 Tracheal Inflammation Persists in Allethrin Exposed Rats 21 Days Post-exposure

Animals exposed to the different forms of allethrins i.e. Baoma and wave tide fume-exposed groups (exhibited significant differences among groups with p-value of 0.099 and 0.044 21 days post-exposure. The lymphocytic infiltration in animals exposed to dichlorvos was

remarkable though, statistically insignificant. Animals exposed to rich-d-trans allethrin showed the most severe inflammatory features. Inflammatory infiltrates appears to have reduced in animals receiving pure allethrins but vascular congestion worsened compared to those exposed for 14 days.

**4. DISCUSSION**

Several respiratory problems such as Chronic Obstructive Pulmonary Diseases and even lung cancers have been attributed to many environmental pollutions such as inhalation of tobacco smoke, paint fumes, asbestoses, smoke from wire wood, in cents sticks and mosquito coil [8,9]. Burning of mosquito coil is a common practice in low socio-economic rural areas of sub-tropical Africa (Nigeria inclusive) and Asia [4]. Many research has been conducted to understand the effect of mosquito repellent on human health, early researches by Liu and Wong, [10], Liu and Sahu [11], Cheng et al. [12, 13], suggests that exposure to the smoke of mosquito coils can pose significant acute and chronic health risks. A study carried out by Liu et al. [14], observed that exposure to mosquito coil elevates the risk of lung cancer in Taiwan. This study has as well recorded similar and distinct observations both physically and microscopically. The behavioural signs that were observed in this study which include irritation of the eyes and nostrils, scratching of nostrils and closing of the eyes, sneezing, gurgling, ruffled fur and lethargy are in line with previous studies by Taiwo et al. [15].

The effect of the various selected mosquito repellent used in this study showed no significant effect on the bodyweight of Wistar rats, this conforms with the observation of Balogun et al., [16] who reported that there was no significant loss in body weight of rats exposed to paint fumes for five weeks. This is in contrast with the study of Ayorinde et al., [7], which recorded significant change in body weight/ lung indices of male rats after 4 weeks of exposure to a higher dosage of repellents. This may be because the animals were exposed to higher dose for a long period and may also be due to many factors like environment, feeds, weather, gender, age, specie of animal as well as the difference in the brand and components of repellent used in these studies.

The effects of inhalation of selected mosquito repellents on the gross feature of the trachea show no significant difference (p<0.05). Frothy trachea, consistent with the findings of Taiwo et al. [15] was observed in animals exposed for 21days with baoma fume-exposed rats showing higher mean rank when compared to others. This disparity may be as a result of the difference in the brand component in their abilities to irritate the trachea. However, animals to rich-d-trans allethrins had more severe features compared to animals receiving `pure` allethrins. This stereoisomer of the compound might prove to be more toxic and subsequently a more prominent irritant than the pure form of allethrin.

**Table 4. Tracheal changes 14 days post-exposure to selected mosquito repellents**

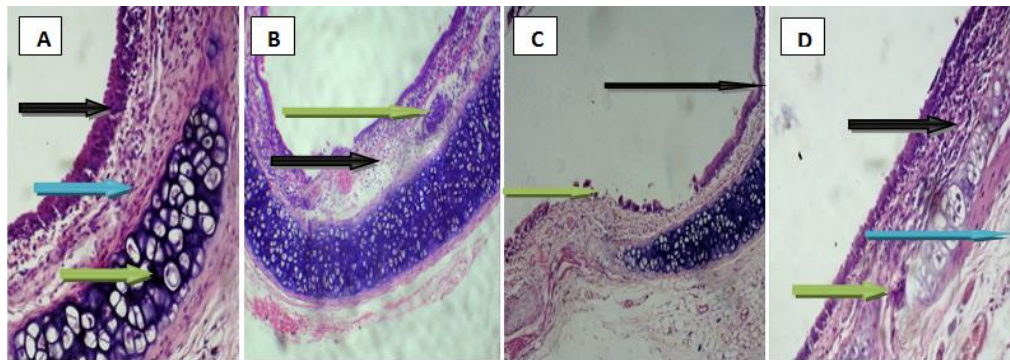
Group	Change scores (Mean rank)		
	Epithelial disruption	Lymphocytic infiltration	Vascular congestion
A(Control)	5.00	4.00	2.50
B(Wavetide)	7.67	12.17 <sup>a</sup>	9.83
C(Baoma)	11.00 <sup>a</sup>	8.50	10.50 <sup>a</sup>
D(Rambo)	9.50	9.67	8.17
E(Sharp)	5.67	5.67	9.00
P-Value	0.380	0.127	0.151

*Mean rank having different superscript are significantly different (p≤0.05) (Kruskal Wallis comparison test)*

**Table 5. Tracheal changes 21 days post-exposure to selected mosquito repellent**

Group	Change scores (Mean rank)		
	Epithelial disruption	Lymphocytic infiltration	Vascular congestion
A(Control)	2.00	3.00	2.00
B(Wavetide)	8.83	6.67	10.67 <sup>a</sup>
C(Baoma)	13.33 <sup>a</sup>	8.33	11.50 <sup>a</sup>
D(Rambo)	7.00	8.50	7.00
E(Sharp)	8.83	13.50	8.83
P-Value	0.099	0.221	0.044

*Mean rank having different superscript are significantly different (p≤0.05) (Kruskal Wallis comparison test)*



**Fig. 1. Photomicrograph A (Control) showing normal histology of tracheal lumen Ciliated pseudostratified columnar epithelium (Black arrow), submucosa (blue arrow), the ring of cartilage (Green arrow). Photomicrograph tracheal lumen B (Rambofume-exposed rat 14 days post-exposure) showing Lymphocyte infiltration (Black arrow) and vascular congestion (Green arrow) of the submucosa. Photomicrograph of tracheal lumen C (Baoma fume-exposed rat 14 days post-exposure). The two arrows indicate areas with epithelial sloughing. Photomicrograph of tracheal lumen D (Baoma fume-exposed rat 7 days post-exposure). Black arrow indicates areas of epithelial metaplasia while Green arrow indicates areas of lymphocyte infiltration (H&E x100)**

Histological studies revealed morphological changes in the trachea of fume-exposed rats. The changes observed in the trachea include epithelial lining disruption, lymphocytic infiltration and vascular congestion. These are all features of inflammation and indicate the presence of an irritant. The animals in the control group have the lowest score when compared with the baoma-fume exposed animals with a statistically significant difference ( $p < 0.05$ ), 7 and 21 days post-exposure. Wave tide mosquito coil has the highest mean rank 14 days post-exposure. This is in line with the previous report of the disrupted tracheal epithelium, epithelial damage, paralyzed cilia and amalgamation of cilia by Ziad and Hossam, [17] after exposure of rats to tobacco smoke. This further supports the irritant nature of smoke in the repellents as the usual mode of operation is by burning the coils slowly like an incense.

The study has shown that certain compounds in mosquito repellents (especially allethrin) currently used among resource-poor individuals in resource-poor settings are potentially toxic and their long term effects can not be ignored. However, this study is limited to the overall effect of the fumes and we do not understand completely if the smoke contributes to the pathologic effects or not. Nevertheless, animals exposed to rich-d-trans allethrin showed a worse outcome in the trachea of the animals indicating its inflammatory potency. This might lead to further respiratory health problems if exposure persists.

## 5. CONCLUSION

Exposure of adult Wistar rats to mosquito repellent for a short period have no significant effect on the bodyweight of Wister Rats as weight gain was observed in 14 and 21 days post-exposure.

Acute exposure of Wister rats to selected mosquito repellents have toxic effects on the gross features of the trachea with the significant effect seen 21 days post-exposure.

Acute exposure of Wister rats to selected mosquito repellents have toxic effects on the normal histological architecture of the trachea evidenced by varying degrees of pathological changes recorded.

Gross and histological features seen in allethrin-exposed rats (particularly rich-d-trans allethrin) had the most severe inflammatory features observed in this study.

Policymakers and interested parties should implement proper screening and authentication of malaria preventive measures as some of these agents might do more harm than good in the long run.

## ETHICAL APPROVAL

Ethical approval for this research was sought from the Ethics and Research Committee for the

Use of Animals in Research of the Usmanu Danfodiyo University, Sokoto.

### COMPETING INTERESTS

Authors have declared that no competing interests exist.

### REFERENCES

1. Singh I. Human Histology. New Delhi: Jaypee Brothers Medical Publishers, B-3 EMCA House. 2005;23:223.
2. World Health Organization (WHO). World Malaria Report. World Health Organization, Geneva, Switzerland; 2010a.
3. World Health Organization (WHO). World Malaria report; 2016.
4. Okine LKN, Nyarkoi AK, Armah GE, Awumbila B, Owusu K, Set-Soafia S, Ofosuhenei M. Adverse effect of mosquito coil smoke on lung, liver and certain drug metabolizing enzymes in male Wistar Albino rats. Ghana Medical Journal. 2004; 38:1-13.
5. Dworkin B. How to avoid mosquito bites-DEET repellents must be used with care; 2002. Available:<http://www.drbarrydworkin.com/2002/06/22/how-to-avoid-mosquito-bites-deet-repellents-must-be-used-with-care/>
6. Thatheyus AJ, Selvam A, Deborah G. Synthetic pyrethroids: Toxicity and biodegradation. Applied Ecology and Environmental Sciences. 2013;1(3): 33–36.
7. Ayorinde A, Obboh B, Otubanjo O, Alimba A, Odeigah P. Some toxicological effects of a commonly used mosquito repellent in Lagos State, Nigeria. Research Journal Environmental Toxicology. 2014;8:46–52.
8. Chen SC, Wong RH, Shiu LJ, Chiou MC, Lee H. Exposure to mosquito coil smoke may be a risk factor for lung cancer in Taiwan. Journal of Epidemiology. 2008;18 (1):19-25.
9. Al-Numair K, Barber-Heidal K, Al-Assaf A, El-Desoky G. Water-pipe (Shisha) smoking influences total antioxidant capacity and oxidative stress of healthy Saudi males. International Journal of Food, Agriculture and Environment. 2007;5:17-22.
10. Liu WK, Wong MH. Toxic effects of mosquito coil (A mosquito repellent) smoke on rats. Toxicol Lett. 1987;39:223–239.
11. Liu WK, Sahu SE. Ultrastructural changes of tracheal epithelium and alveolar macrophages of rats exposed to mosquito-coil smoke. Toxicology. Lett. 1988;41: 145-157.
12. Cheng V, Lee HR, Chen CS. Morphological changes in the respiratory system of mice after inhalation of mosquito coil smoke. Toxicol. Lett. 1992;62: 163–177.
13. Al-Numair K, Barber-Heidal K, Al-Assaf A, El-Desoky G. Water-pipe (Shisha) smoking influences total antioxidant capacity and oxidative stress of healthy Saudi males. International Journal of Food, Agriculture and Environment. 2007;5:17-22.
14. Liu W, Zhang J, Hashim JH, Jalaludin J, Hashim Z, Goldstein BD. Mosquito coil emissions and health implications. Environmental Health Perspectives. 2003; 111(12):1454–1460.
15. Taiwo VO, Nwagbara ND, Suleiman R, Angbashim JE, Zarma MJ. Clinical signs and organ pathology in rats exposed to graded dose of pyrethroids containing mosquito smoke and aerosolized insecticidal spray. African Journal of Biomedical Research. 2008;11:97-104.
16. Balogun WG, Ibrahim RB, Ishola AO, Imam A, Adeyemo KA, Alabi AS, Enaibe BU. Histological changes in the lungs of adult Wistar Rats following exposure to paint fumes. Anatomy Journal of Africa. 2014;3(2):329-335.
17. Ziad AS, Hossam NN. Histological changes in tissues of trachea and lung alveoli of albino rats exposed to the smoke of two types of Narghile Tobacco products. Jordan Journal of Biological Sciences. 2011;4(4):219-224.

© 2019 Abdulaziz et al.; This is an Open Access article distributed under the terms of the Creative Commons Attribution License (<http://creativecommons.org/licenses/by/4.0>), which permits unrestricted use, distribution, and reproduction in any medium, provided the original work is properly cited.

Peer-review history:  
The peer review history for this paper can be accessed here:  
<http://www.sdiarticle4.com/review-history/53554>