

# **Retinopathy Associated with Adjuvant Interferon in a Patient with Malignant Melanoma: A Case Report and Review of the Literature**

**Mahmut Dogan<sup>1\*</sup>**

<sup>1</sup>*Luleburgaz State Hospital, Ophthalmology Clinic, Luleburgaz, Kırklareli, Turkey.*

## **Author's contribution**

*The sole author designed, analysed, interpreted and prepared the manuscript.*

## **Article Information**

DOI: 10.9734/OR/2019/V11i230121

### Editor(s):

(1) Dr. Stephen G. Schwartz, Department of Clinical Ophthalmology, Bascom Palmer Eye Institute, University of Miami, Miller School of Medicine, USA.

### Reviewers:

(1) Ștefan Țălu, The Technical University of Cluj-Napoca, Romania.  
(2) Umezurike Benedict Chidozie, Government House Clinic, Nigeria.  
Complete Peer review History: <http://www.sdiarticle4.com/review-history/52921>

**Case Report**

**Received 11 September 2019**  
**Accepted 21 November 2019**  
**Published 27 November 2019**

## **ABSTRACT**

Interferons are kinds of proteins with immunoregulatory, antiviral and anti-proliferative functions. Interferons are widely used worldwide for the treatment of many diseases including cancer, hepatitis C and immune mediated disease such as multiple sclerosis. Long-term use of interferons have some side effects. However, interferons have ophthalmologic side effects. Ocular toxicity may occur at any time during treatment. There is no association between the dose or duration of interferon treatment and ocular toxicity. Although visual acuity returns to normal in most patients when interferon is discontinued, vision loss may be permanent.

*Keywords: Interferon; retinopathy; melanoma; adjuvant.*

## **1. INTRODUCTION**

Interferons are kinds of proteins with immunoregulatory, antiviral and anti-proliferative functions. Interferons are widely used worldwide

for the treatment of many diseases including cancer, hepatitis C and immune mediated disease such as multiple sclerosis. Psychiatric [1,2] cutaneous [3], endocrine [4], hematological [5], and hepatic [6] side effects have been reported

\*Corresponding author: E-mail: mahmutdogan13@gmail.com;

with long term interferon use. However, interferons have some ophthalmologic side effects. Ocular toxicity may occur at any time during treatment; there is no association between the dose or duration of interferon treatment and ocular toxicity. Although visual acuity returns to normal in most patients when interferon is discontinued, vision loss may be permanent [7,8].

Interferon has been used as adjuvant treatment for melanoma for a long time. Interferon can produce longer relapse-free survival in patients with moderate to high-risk disease after curative surgery [9]. The case described above is an interferon-associated retinopathy. Visual field and responses with mfERG (multifocal electroretinography) were dramatically improved shortly after discontinuation of interferon and no other pathology was found to explain the loss of visual acuity can be a proof of interferon associated retinopathy.

Although the etiopathogenesis of interferon related retinopathy is not fully explained, it is believed to be the result of disorders in retinal microcirculation induced by immunological phenomena [10]. Interferon treatment is known to cause or exacerbate systemic autoimmune diseases [11]. Decreased capillary perfusion in the retina, retinal ischemia and non-perfusion can cause cotton wool spot and bleeding. These retinal changes have been hypothesized to be the result of increased accumulation of immune complexes [12], leukocyte aggregation secondary to complement activation [13], inflammatory cell infiltration, and circulating effector proteins [14]. Also interferon is known to reduce vascular endothelial migration and proliferation and cause poor endothelial repair and this may be another mechanism for vascular occlusive events in the retina [15].

It was emphasized by some authors that specific risk factors during interferon use may play a role in the development of ophthalmologic complications. In 1998, Hayasaka et al. examined the subjects [16] and concluded that systemic hypertension and diabetes mellitus were clear risk factors for eye disease during treatment with interferons.

Cutaneous, hematologic, psychiatric, endocrine, and hepatic monitoring are well established by guidelines. On the other hand, the ophthalmologic side effects of interferons are not well known and there are no guidelines or

recommendations for monitoring patients through regular ophthalmological consultations.

## **2. CASE**

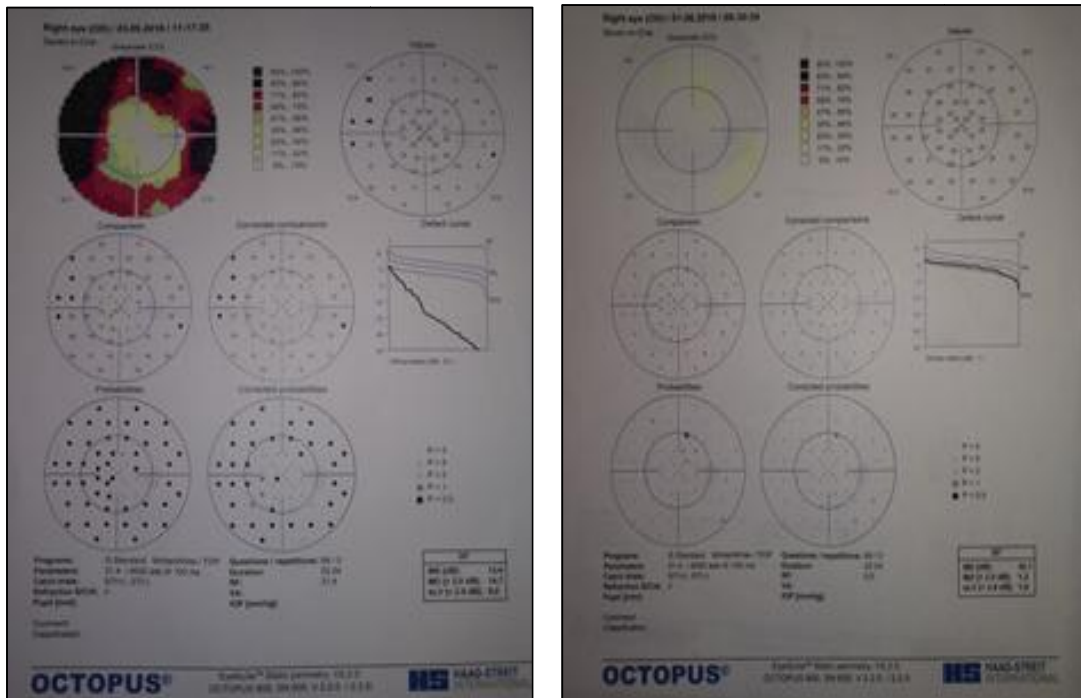
A 50-year-old male with complaint of blurred vision in both eyes. He was receiving interferon beta for 3 months as adjuvant therapy for malignant melanoma. The visual acuity (according to snellen chart) was 0.4 in the right eye and 0.7 in the left eye. The anterior and posterior segment examinations of eyes were normal. Fundoscopic retinal examination revealed no pathology. The optic disc and macular region were observed normal. Light reflex was normal, RAPD (relative afferent pupillary defect) was not observed, eye movements were normal in all directions, no double vision was observed. Macular – OCT (optic coherence tomography) imaging was normal. Visual field testing, there were peripheral concentric constriction scotomas on the right eye and nasal, temporal scotomas on the left eye (Fig. 1 and Fig. 2). VEP (visual evoked potential) and mfERG (multifocal electroretinogram) tests were performed on same day. P100 amplitude and latence were normal in VEP, but the mfERG waves were decreased (Fig. 3 and Fig. 4). After eye examination, this situation was thought to be related to interferon treatment. It was recommended to discontinue the drug.

One week later, he had normal vision in both eyes. The patient had no blurred vision complaint. All scotomas in the visual field were improved (Fig. 1 and Fig. 2). There was a significant improvement in the control mfERG test compared to mfERG one week earlier. (Fig. 3 and Fig.4) There was no difference in VEP tests (Fig. 5).

## **3. DISCUSSION**

There are few articles on the prevalence of visual side effects in the patient population using interferon.

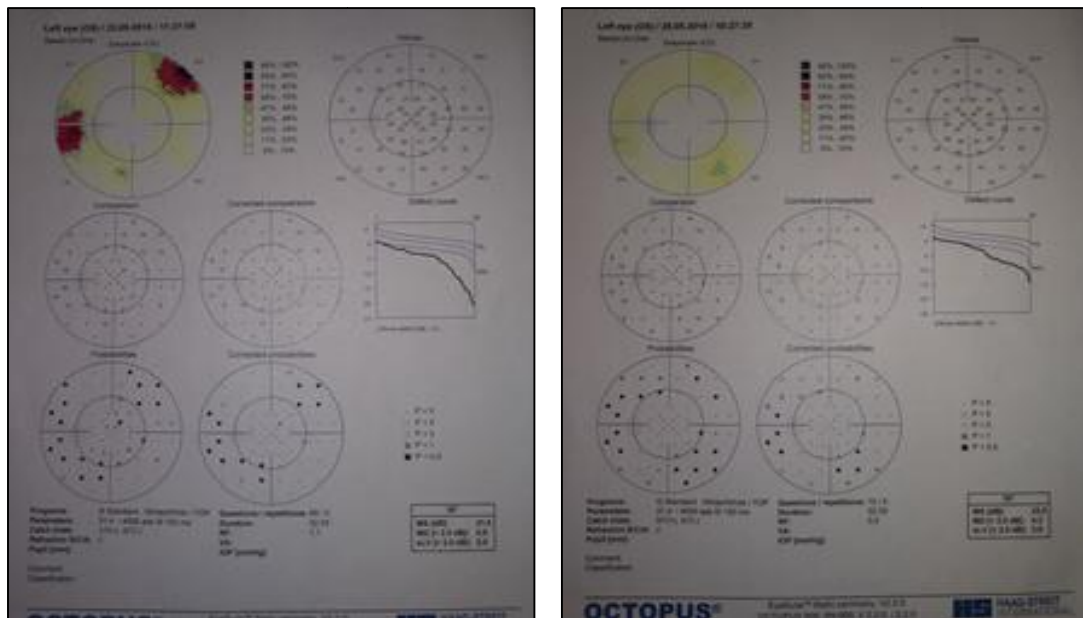
In 1990, Ikebe et al. first reported a 39 year old patient with retinal hemorrhages and cotton wool spots following intravenous administration of interferon [17]. Another report [18] showed that 8.4% of interferon-related adverse effects affected the eye. However, some prospective studies have linked interferon treatment with a variable incidence of retinopathy from 18% to 86% [19].



A

B

Fig. 1. Visual field testing, there was peripheral concentric constriction scotoms in the right eye under interferon beta treatment (A), after interferon treatment discontinued scotoms were disappear same eye after one week (B)



C

D

Fig. 2. Visual field testing, there were nasal and temporal scotoms on the left eye (C), after interferon treatment discontinued scotoms were disappear same eye after one week (D)

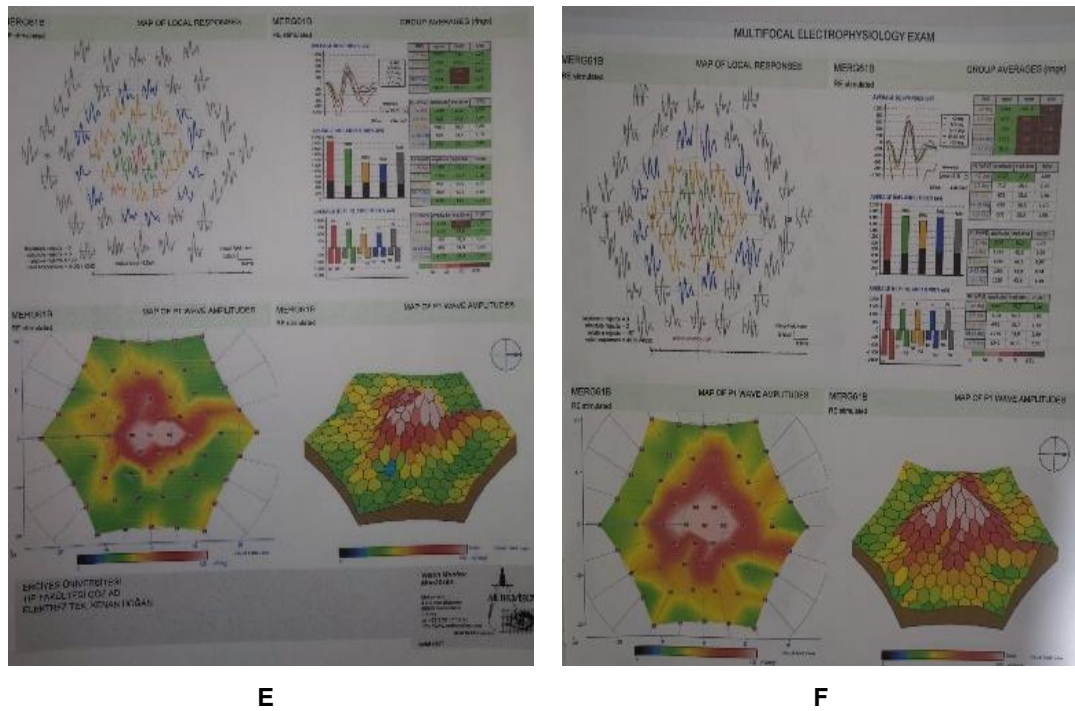


Fig. 3. mfERG(multifocal electroretinogram) test, there was decreased amplitude of waveform under interferon beta treatment in the right eye(E); after interferon treatment discontinued amplitude of waveform were increased same eye after one week (F)

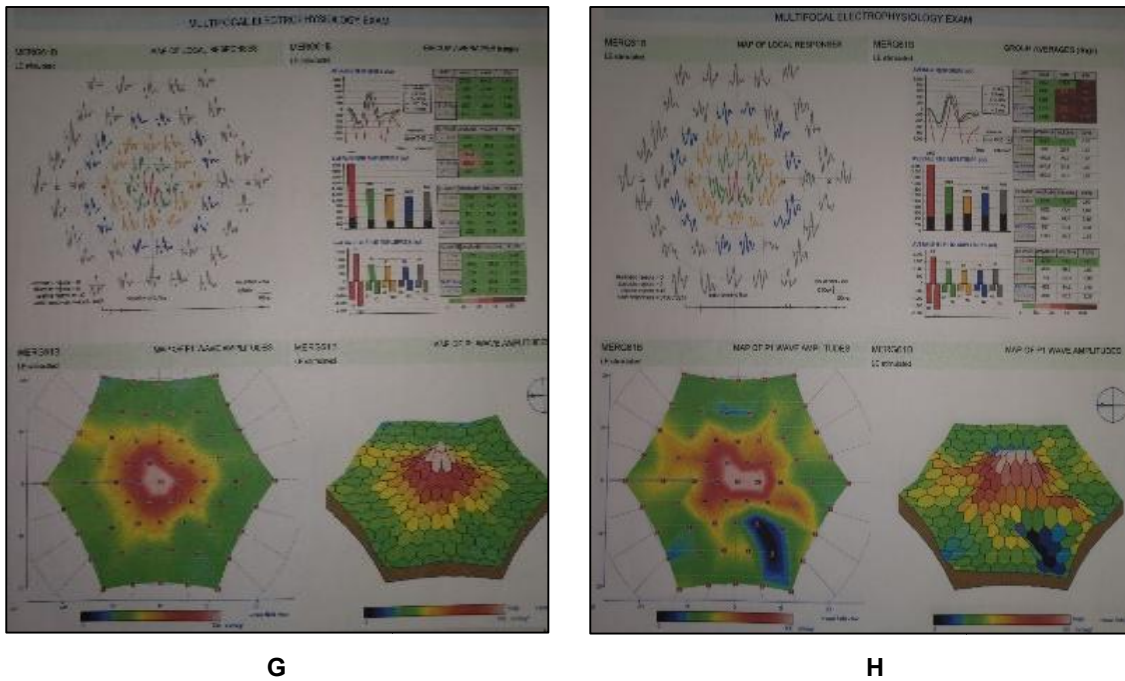
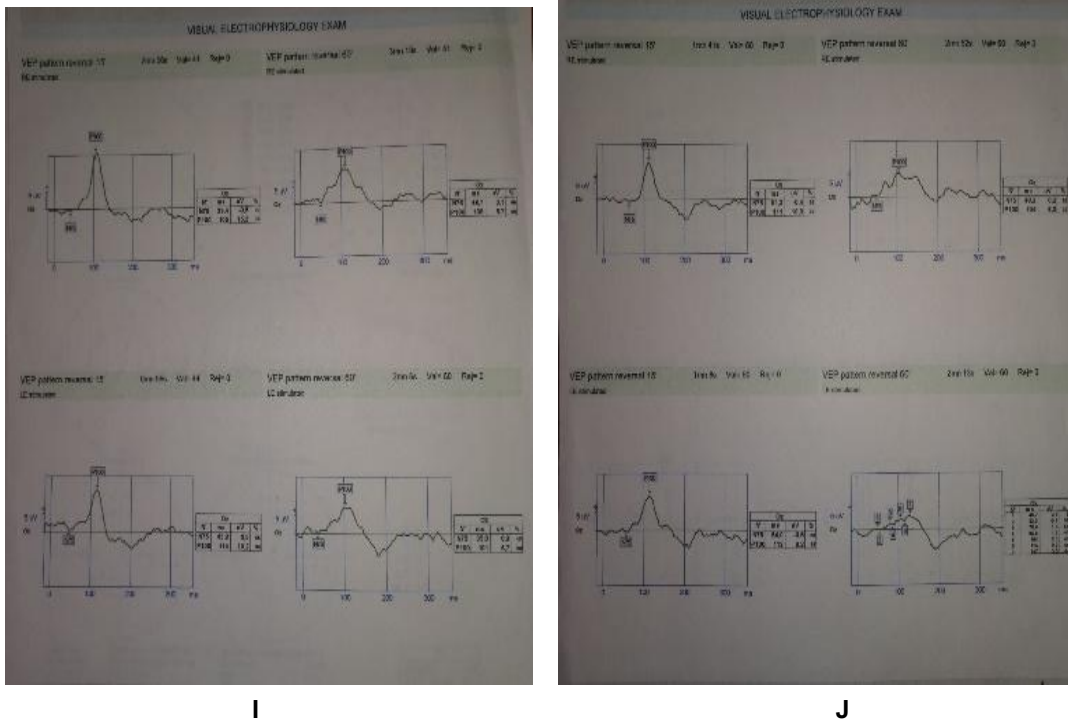


Fig. 4. mfERG(multifocal electroretinogram) test, there was decreased amplitude of waves under interferon beta treatment in the left eye(G); after interferon treatment discontinued amplitude of waves was increased same eye after one week (H)



**Fig. 5. VEP (visual evoked potential) there was normal both eyes P100 wave amplitude under interferon beta treatment (I); after interferon treatment discontinued amplitude of P100 wave not changed both eyes after one week (J)**

Kadayıfçılar and et al. reported 42% incidence of retinopathy with cotton wool spot formation and splinter hemorrhages in patients who were under high-dose interferon alpha treatment for chronic active hepatitis [20].

Cuthbertson FM and et al. have found 16% incidence of retinopathy in patients receiving interferon alpha treatment for chronic active hepatitis [21].

The majority of these studies were in patients with hepatitis C, where interferon was administered at lower doses than melanoma treatment. In a small series of 30 patients with high-risk melanoma receiving residual high dose interferon, 13% of patients developed retinopathy [22]. All of these patients were asymptomatic and retinopathy was detected only on routine ophthalmologic examination. Patients with melanoma that becomes symptomatic after interferon related retinopathy typically presented with progressive mild visual impairment [23,24].

The most common abnormalities observed were cotton wool spots and bleeding on their retina. The changes in the retinal capillary walls lead to capillary closure [25]. Other documented ocular

complications of interferon treatment in melanoma patients include macular edema [26,27], microaneurysms [26], retinal capillary non-perfusion [26], and anterior ischemic optic neuropathy (AION) [28]. Interferon-related ocular toxicities in other disease settings include increased intraocular pressure [29], neovascular glaucoma [30] and retinal detachment [31].

The actual extent of ophthalmologic adverse effects caused by interferons may not be known, as ophthalmological investigation of these patients were performed when patients complained of visual symptoms. In addition to the problem, the underlying diseases themselves can also cause visual symptoms. For example, blurred vision may be due to optic neuritis, and diplopia may be associated with brainstem lesions in multiple sclerosis [32,33]. Uveitis and retinal phlebitis have been reported as retinal symptoms of multiple sclerosis [34] and may contribute to the difficult differential diagnosis of visual disturbances in a patient with multiple sclerosis and receiving interferon. Therefore, ophthalmologist may think that the underlying disease worsens when the symptoms may have a negative effect on the treatment. These ocular changes may occur as early as 3 weeks to



several months after starting the drug treatment. Despite the discontinuation of interferon, there have been some cases of irreversible visual impairment, but these have been associated with presentation and low visual acuity in anterior ischemic optic neuropathy (AION) [14,17]. In one reported case, there was no improvement in retinopathy despite aggressive treatment with acetylsalicylic acid, dexamethasone, heparin and cyclosporine [27]. Fortunately, these serious cases of retinopathy are rare, and in most milder cases, retinal changes are resolved by interferon discontinuation.

#### 4. CONCLUSION

Patients should be informed about this potential complication, Patients suffering from visual symptoms should undergo complete ophthalmologic examination. Because no screening protocol have been suggested, ophthalmologists and oncologists should be alert. Interferon treatment should be discontinued if retinopathy occurs. Nowadays there is no guideline for the restarting interferon treatment after the ocular toxicity occurred. This decision must be personalized after careful consideration of the principles and risks.

#### CONSENT

'Written informed consent' was obtained from the patient (or other approved parties) for publication of this case report and accompanying images.

#### ETHICAL APPROVAL

We have obtained all necessary ethical approval from suitable State Committee. We confirm either that this study is not against the public interest, or that the release of information is allowed by legislation.

#### COMPETING INTERESTS

Author has declared that no competing interests exist.

#### REFERENCES

1. Sockalingam S, Abbey SE. Managing depression during hepatitis C treatment. *Can J Psychiatry*. 2009;54(9):614-25.
2. Fragoso YD, Frota ER, Lopes JS, Noal JS, Giacomo MC, Gomes S, et al. Severe depression, suicide attempts, and ideation during the use of interferon beta by patients with multiple sclerosis. *Clin Neuropharmacol*. 2010;33(6):312-6.
3. Orășan O, Cozma A, Rednic N, Sâmpolean D, Pârnu A, Petrov L. Anemia—a complication of antiviral treatment in chronic viral hepatitis C. *Rom J Intern Med*. 2009;47(3):217-25.
4. Nonchev BI. Cases of interferon-alpha and interferon-beta-induced thyroiditis. *Folia Med (Plovdiv)*. 2010;52(3):5-12.
5. Mistry N, Shapero J, Crawford RI. A review of adverse cutaneous drug reactions resulting from the use of interferon and ribavirin. *Can J Gastroenterol*. 2009;23(10):677-83. Erratum in *Can J Gastroenterol*. 2009;23(11):784.
6. Tremlett H, Oger J. Hepatic injury, liver monitoring and the beta-interferons for multiple sclerosis. *J Neurol. Review*. 2004;251(11):1297-303.
7. Axel Hauschild MD, et al. Practical guidelines for the management of interferon- $\alpha$ -2b side effects in patients receiving adjuvant treatment for melanoma. *Cancer*. 2008;112(5):982-994.
8. Borden EC, Parkinson D. A perspective on the clinical effectiveness and tolerance of interferon-alpha. *Semin Oncol*. 1998;25(Suppl 1):3-8.
9. Kirkwood JM, Strawderman MH, Ernstoff MS, et al. Interferon alfa-2b adjuvant therapy of high-risk resected cutaneous melanoma: The Eastern Cooperative Oncology Group Trial EST 1684. *J Clin Oncol*. 1996;14:7-17.
10. Guyer DR, Tiedeman J, Yannuzzi LA, et al. Interferon-associated retinopathy. *Arch Ophthalmol*. 1993;111:350-356.
11. Borg FA, Isenberg DA. Syndromes and complications of interferon therapy. *Curr Opin Rheumatol*. 2007;19:61-66.
12. Guyer DR, Tiedeman J, Yannuzzi LA, et al. Interferon-associated retinopathy. *Arch Ophthalmol*. 1993;111:350-356.
13. Sugano S, Yanagimoto M, Suzuki T, et al. Retinal complications with elevated circulating plasma C5a associated with interferon-alpha therapy for chronic active hepatitis C. *Am J Gastroenterol*. 1994;89:2054-2056.
14. Hejny C, Sternberg P, Lawson DH, et al. Retinopathy associated with high-dose interferon alfa-2b therapy. *Am J Ophthalmol*. 2001;131:782-787.
15. Brouty-Boyé D, Zetter BR. Inhibition of cell motility by interferon. *Science*. 1980;208:516-518.
16. Hayasaka S, Nagaki Y, Matsumoto M, Sato S. Interferon associated retinopathy.

- Br J Ophthalmol. Review. 1998;82(3):323-5.
17. Ikebe T, Nakatsuka K, Goto M, Sakai Y, Kageyama S. A case of retinopathy induced by intravenous administration of interferon. *Folia Ophthalmol Jpn (Ganka-Kiyo)*. 1990;41:2291-6.
  18. Ockenfels M, Lisch W. Ocular complications of adjuvant interferon therapy for malignant melanoma: A review]. *Hautarzt. German*. 2003;54(2): 144-7.
  19. Hayasaka S, Nagaki Y, Matsumoto M, et al. Interferon associated retinopathy. *Br J Ophthalmol*. 1998;82:323-325.
  20. Sibel Kadayifcilar, Sedat Boyacioglu, Hamide Kart, Murat Gursoy, Pinar Aydin. Ocular complications with high-dose interferon alpha in chronic active hepatitis. 1999;13:241-246.
  21. Cuthbertson FM, Davies M, McKibbin M. Is screening for interferon retinopathy in hepatitis C justified? *Br J Ophthalmol*. 2004;88(12):1518-20.
  22. Sulkes A, Schachter J. Comment on Perhaps not everyone knows that. (*Ann Oncol* 2001;12:1186) *Ann Oncol*. 2002;13:637.
  23. Guyer DR, Tiedeman J, Yannuzzi LA, et al. Interferon-associated retinopathy. *Arch Ophthalmol*. 1993;111:350-356.
  24. Hejny C, Sternberg P, Lawson DH, et al. Retinopathy associated with high-dose interferon alfa-2b therapy. *Am J Ophthalmol*. 2001;131:782-787.
  25. Ștefan Țălu, Dan Mihai Călugăru, Carmen Alina Lupașcu, Characterisation of human non-proliferative diabetic retinopathy using the fractal analysis. *International Journal of Ophthalmology (English edition)*. 2015; 8(4):770-776. DOI: 10.3980/j.issn.2222-3959.2015.04.23
  26. Guyer DR, Tiedeman J, Yannuzzi LA, et al. Interferon-associated retinopathy. *Arch Ophthalmol*. 1993;111:350-356.
  27. Hejny C, Sternberg P, Lawson DH, et al. Retinopathy associated with high-dose interferon alfa-2b therapy. *Am J Ophthalmol*. 2001;131:782-787.
  28. Lohmann CP, Kroher G, Bogenrieder T, et al. Severe loss of vision during adjuvant interferon alfa-2b treatment for malignant melanoma. *Lancet*. 1999;353: 1326.
  29. Kuga K, Hasumura S, Nagamori S, et al. Intraocular hemorrhage developing during interferon therapy. *Intern Med*. 1996;35: 15-18.
  30. Ayaki M. Development of neovascular glaucoma in the course of interferon alfa therapy for hepatitis type C. *Br J Ophthalmol*. 1994;78:238.
  31. Okanoue T, Sakamoto S, Itoh Y, et al. Side effects of high-dose interferon therapy for chronic hepatitis C. *J Hepatol*. 1996;25: 283-291.
  32. Simao LM. Ophthalmologic manifestations commonly misdiagnosed as demyelinating events in multiple sclerosis patients. *Curr Opin Ophthalmol*. 2010;21(6):436-41.
  33. Prasad S, Galetta SL. Eye movement abnormalities in multiple sclerosis. *Neurol Clin*. 2010;28(3):641-55.
  34. Kerrison JB, Flynn T, Green WR. Retinal pathologic changes in multiple sclerosis. *Retina*. 1994;14(5):445-51.

© 2019 Dogan; This is an Open Access article distributed under the terms of the Creative Commons Attribution License (<http://creativecommons.org/licenses/by/4.0>), which permits unrestricted use, distribution, and reproduction in any medium, provided the original work is properly cited.

*Peer-review history:*

*The peer review history for this paper can be accessed here:*  
<http://www.sdiarticle4.com/review-history/52921>