



## Investigation of Root-crown Ratio of Upper Incisors in a Group of Turkish Adolescent

Bilal Ozmen<sup>1</sup>, Nazlı Basak Ayna<sup>1</sup> and Zeynep Kaya<sup>1\*</sup>

<sup>1</sup>Department of Pediatric Dentistry, Faculty of Dentistry, Ondokuz Mayıs University, Samsun, Turkey.

### Authors' contributions

This work was carried out in collaboration among all authors. Author BO designed the study, performed the statistical analysis, wrote the protocol and managed the analyses of the study. Authors ZK and NBA wrote the first draft of the manuscript, managed the literature searches. All authors read and approved the final manuscript.

### Article Information

#### Editor(s):

(1) Dr. M. Jaya Nagendra Krishna, Kamineni Institute of Dental Sciences, India.

#### Reviewers:

(1) Tara Ali Rasheed, University of Sulaimani, Iraq.

(2) Marcela Martín del Campo Fierro, Universidad Autónoma de San Luis Potosí (UASLP), Mexico.

Complete Peer review History: <http://www.sdiarticle4.com/review-history/67708>

Original Research Article

Received 27 February 2021

Accepted 04 May 2021

Published 22 May 2021

### ABSTRACT

**Aims:** The aim of this study was to evaluate of the root-crown ratio in upper incisors using panoramic radiographs in a group of Turkish Adolescent.

**Study Design:** Various measurements were made on panoramic radiographs in the study.

**Place and Duration of Study:** Ondokuz Mayıs University, Faculty of Dentistry, Department of Pedodontics between June 11, 2019 and December 11, 2020.

**Methodology:** In this study, the crown heights and root lengths of the upper incisor teeth were measured in digital panoramic radiographs of 568 Adolescent [284 girls, 284 boys] aged between 13-14 years. No patients with any systemic disease or syndrome, filling or caries in their upper incisor teeth were included. Measurements were made under dim light using Image J program. Crown heights and root lengths were measured using modified Lind's method. One-Way Analysis of Variance and Tukey multiple comparison test were used in the analysis of the data.

**Results:** No statistical difference was detected between root lengths of the teeth [ $p=0.13$ ]. Crown heights of central teeth were longer than lateral teeth [ $p<0.001$ ]. The highest root-crown ratios were determined in lateral teeth [ $p<0.001$ ]. Similar root-crown ratios were found in symmetrical teeth.

**Conclusion:** This study may provide convenience to dentists when the root length of teeth in need of root canal treatment cannot be determined by radiographs or in cases where digital root length

\*Corresponding author: Email: zeynepkaya.2508@hotmail.com;

measuring devices are not available. It can also guide the estimation of crown height and root lengths of upper incisors in Turkish Adolescent.

**Keywords:** *Child patient; panoramic radiography; root-crown ratio; lateral tooth; central tooth; upper jaw.*

## 1. INTRODUCTION

Knowing the crown and root lengths of the teeth and the ratio of these lengths are important factors for proper dental treatments. Especially in traumatized teeth, the root-crown ratio becomes more important. Traumatic dental injuries are frequently seen in Adolescent and young patients and may require emergency treatment [1]. Excessive substance loss may occur in the teeth and, depending on the type of injury, teeth may lose their vitality in the early or late period [2]. If the root-crown ratio of the tooth changes depending on the amount of substance loss in the tooth, the prognosis of the tooth and the treatment planning of the patient will be affected by this situation. Therefore, considering the crown-root ratio, the appropriate restoration type is determined [3,4].

In endodontic treatments, firstly, the working length should be determined to stay within the boundaries of the root canal system [5]. As a result of the working length determined longer than normal, overflowing causes foreign body reaction in the peri-radicular region. When the working length is determined incompletely, healing cannot be expected because the infected tissues cannot be cleaned completely [6,7]. Many methods are used to determine the working length. Canal instruments placed in the root canal and radiographs are mostly used. The use of electronic apex locators is increasingly common [8]. Knowing the average root-crown ratio or root length of the teeth supports these methods.

In orthodontic treatments, knowing the root length can help the orthodontists for the healthy progress of the treatment. Root resorption induced by the treatment is observed in teeth receiving orthodontic treatment. Microscopic resorption occurs in all teeth during orthodontic movement, but sometimes it is possible to occur severely [9]. It is known that this risk is higher in teeth with short roots compared to teeth with average roots length [10]. For this reason, knowing the root lengths of the teeth is also important in orthodontic treatments.

In forensic dentistry, skull and tooth features may be used to determine gender. Crown and root lengths of teeth are characteristic for the genders and facilitate estimation for forensic physicians [11,12].

Panoramic radiographs are often used to view anatomical structures and teeth. They can also be used to determine crown height and root length [13,14]. The images on the radiography may be distorted and may show less or more than their actual size. However, this situation has less effect on vertical measurements. In addition, elongation or shortening of the tooth length on the x-ray is not important in vertical measurements [15,16].

When the literature is reviewed, it is seen that the root-crown ratio has been investigated specifically for societies with a limited number of studies, but no such study has been conducted on the Turkish population [13,17-19]. The aim of this study is to evaluate the root-crown ratio in the upper incisors using panoramic radiographs in a group of healthy Turkish Adolescent.

## 2. METHODOLOGY

In this retrospective study, patients aged 13-14 years, who applied to Ondokuz Mayıs University, Faculty of Dentistry, Department of Pedodontics between June 11, 2019 and December 11, 2020, were included.

Inclusion criteria in the study:

- No systemic disease or syndrome
- Absence of decay and restoration in upper incisors
- No history of orthodontic treatment and severe crowding
- High quality of panoramic radiographs
- Not previously traumatized teeth

Exclusion criteria:

- Presence of a systemic disease and syndrome

- Caries and restoration in at least one of the upper incisors
- Previous orthodontic treatment
- Radiographs of low quality and with no clear reference points
- A history of trauma in the upper incisors
- Shape anomalies in incisors (for example peg shaped lateral)
- Bony lesions attached to root
- Hypercementosis and dilacerations
- Cleft lip and cleft palate
- Radiotherapy and chemotherapy in head and neck

Panoramic radiographs were taken with a digital panoramic x-ray device [Sirona Orthophos XG, Sirona Dental Company, Germany] with 60 kVp, 3mA and 14.1 seconds exposure time. Maxillary central and lateral teeth were examined on digital panoramic film taken from 568 patients [284 boys, 284 girls] who met the inclusion criteria. All radiographs examined were individually calibrated. Image J [Java V.1.8.0\_172], a java based image processing program, was used to measure the root and crown lengths. All measurements were made under dim light.

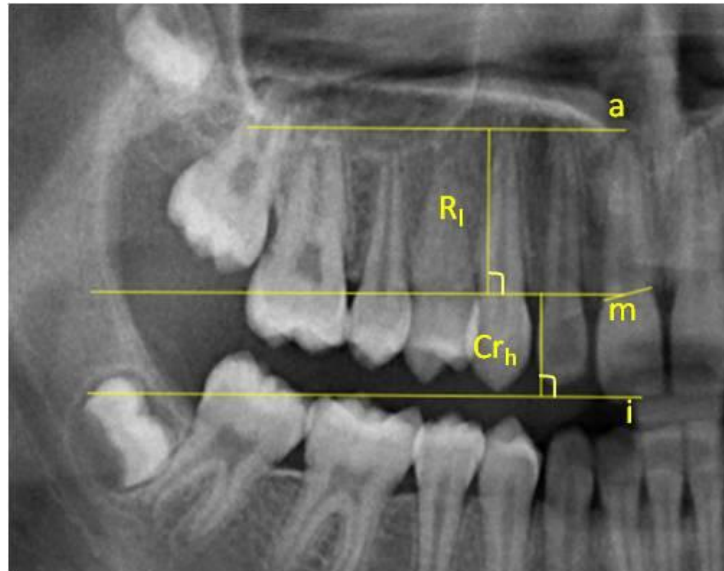
Modified Lind's method was used for measurements [14]. Modified Lind method: i:incisal level, a: apical level, m: midpoint of a straight line that connects the points of

intersection between the outer contours of root and crown. The distances between the parallel lines drawn from the reference points [i, m and a] were measured in mm and the root lengths [Rl] of the teeth and the crown heights [Crh] were determined [Fig. 1]. Root-crown ratio was found by proportioning these lengths.

Shapiro-Wilk normality test was applied to check whether the obtained data showed normal distribution and it was determined that it showed normal distribution [ $P > .05$ ]. For this reason, differences between treatment groups were determined by One-Way ANOVA and Tukey's multiple comparison tests. The findings were expressed as mean, standard deviation, minimum and maximum values, and  $P < .05$  was accepted significance level. All statistical calculations were made in SPSS 22.0 V. statistics package program.

### 3. RESULTS

This study was conducted on the panoramic radiographs of patients who met the inclusion criteria. No statistical difference was detected between root lengths of the teeth [ $P = .13$ ]. The longest root was detected in the maxillary right lateral tooth [21.29 mm]. The shortest roots were measured in the maxillary right and left central teeth [10.33 mm] [Table 1].



**Fig. 1. Modified Lind method. i:incisal level, a: apical level, Rl: root length, Crh: crown height, m: midpoint of a straight line that connects the points of intersection between the outer contours of root and crown**

Crown heights of central teeth were longer than lateral teeth. There was no statistical difference between the crown lengths of symmetrical teeth [ $P < .001$ ]. The shortest crowns were measured in the maxillary right and left lateral teeth [5.99 mm]. The longest crown was detected in the left central tooth [11.62 mm] [Table 1].

The highest root-crown ratios were determined in lateral teeth [ $P < 0.001$ ]. Similar root-crown ratios were found in symmetrical teeth [Table 1]. Similar situations were observed in terms of gender [Table 2 and 3]. In boys, both root lengths and crown lengths were longer than girls.

**Table 1. Crown height, root lengths and root-crown ratio in all patients**

			Root length	Crown height *	Root-crown ratio*
Right side	Lateral teeth	Mean±SD	14.49±1.57	8.02±0.8 <sup>a</sup>	1.82 ±0.23 <sup>a</sup>
		Min	10.48	5.99	1.31
		Max	21.29	10.65	2.96
	Central teeth	Mean±SD	14.74±1.65	9.13±0.8 <sup>b</sup>	1.62±0.18 <sup>b</sup>
		Min	10.33	6.71	1.16
		Max	19.55	11.57	2.11
Left side	Lateral teeth	Mean±SD	14.52±1.53	8.07±0.7 <sup>a</sup>	1.81±0.21 <sup>a</sup>
		Min	10.75	5.99	1.28
		Max	20.17	11.05	2.61
	Central teeth	Mean±SD	14.78±1.61	9.17±0.8 <sup>b</sup>	16.2±0.19 <sup>b</sup>
		Min	10.33	6.84	1.08
		Max	19.15	11.62	2.26
P- value			.13	< .001	< .001

SD: Standard deviation; \* There is a statistical difference between different letters in the same column

**Table 2. Crown height, root lengths and root-crown ratio in the girls**

			Root length	Crown height *	Root-crown ratio*
Right side	Lateral teeth	Mean±SD	13.97±1.48	7.88±0.77 <sup>a</sup>	1.78±0.2 <sup>a</sup>
		Min	10.48	5.99	1.31
		Max	17.14	10.31	2.64
	Central teeth	Mean±SD	14.15±1.51	8.90±0.77 <sup>b</sup>	1.6±0.19 <sup>b</sup>
		Min	10.33	6.71	1.16
		Max	18.29	11.08	2.11
Left side	Lateral teeth	Mean±SD	14.09±1.43	7.87±0.71 <sup>a</sup>	1.8±0.18 <sup>a</sup>
		Min	10.75	5.99	1.40
		Max	17.86	9.9	2.33
	Central teeth	Mean±SD	14.19±1.45	8.94±0.83 <sup>b</sup>	1.6±0.19 <sup>b</sup>
		Min	10.33	6.84	1.20
		Max	17.78	11.46	2.26
P- value			.6	< .001	< .001

SD: Standard deviation; \* There is a statistical difference between different letters in the same column

**Table 3. Crown height, root lengths and root-crown ratio in the boys**

			Root length	Crown height *	Root-crown ratio*
Right side	Lateral teeth	Mean±SD	15±1.49	8.16±0.73 <sup>a</sup>	1.85±0.25 <sup>a</sup>
		Min	11.91	6.22	1.44
		Max	21.29	10.65	2.96
	Central teeth	Mean±SD	15.32±1.56	9.35±0.76 <sup>b</sup>	1.64±0.18 <sup>b</sup>
		Min	11.20	7.5	1.27
		Max	19.55	11.57	2.08
Left side	Lateral teeth	Mean±SD	14.94±1.51	8.27±0.74 <sup>a</sup>	1.82±0.23 <sup>a</sup>
		Min	11.7	6.69	1.28
		Max	20.17	11.05	2.61
	Central teeth	Mean±SD	15.38±1.54	9.39±0.77 <sup>b</sup>	1.65±0.19 <sup>b</sup>
		Min	11.35	7.68	1.08
		Max	19.15	11.62	2.05
P- value			.07	< .001	< .001

SD: Standard deviation; \* There is a statistical difference between different letters in the same column

#### 4. DISCUSSION

In dentistry, crown and root lengths are very important in restorative, endodontic, orthodontic and prosthetic treatments. Although the root length does not show any elongation after the apex is closed, it is possible to change the crown height with restorative and prosthetic treatments. In dental treatments, it is preferred to have a root-crown ratio of at least 1 or more [20,21].

Wang et al. [19] reported that ethnic differences have an effect on tooth development and that the root-crown ratios of societies may vary depending on this difference. Among the studies in which the average root-crown ratios of various societies are reported, there is no such data for the Turkish population [13,14,18]. In the present study, this deficiency has been tried to be compensated and statistical differences were detected in root-crown ratio.

In addition to periapical and panoramic x-rays, which are routinely used in the evaluation of dental tissues, cone beam computed tomography [CBCT] imaging is also used. When studies evaluating the root-crown ratio are examined, it is seen that both panoramic x-rays and CBCT images are used for this purpose [17,19]. Although it is thought that panoramic x-rays are not suitable for measuring tooth length due to their distortion, Stramotas et al. [22] stated that crown height and root length can be measured accurately in panoramic radiographs. In this study, panoramic radiographs were used to determine the crown and root lengths of the maxillary incisor teeth. Panoramic radiographies has some advantages such as all teeth can be seen at the same time, frequently preferred for diagnosis in first appointment, low radiation dose. In addition, CBCT is preferred in more specific situations [23]. In the study, all panoramic radiographs were taken with a single x-ray machine with constant magnification. Magnification that may occur in x-rays images are not cause a change in the root-crown ratio, as it affects both the root and the crowns of the teeth similarly [19].

Dentition, which is a part of growth and development, is affected by genetic, hereditary and environmental factors [24]. Radiation therapy taken in childhood may affect the development of tooth roots, causing them to remain short [25]. Short roots are also seen in syndromes such as Down and Steven Johnsons [26,27]. For this reason, patients with syndrome and systemic

disease were excluded from the study in order not to affect the measurements. In addition, individuals with trauma and caries in their maxillary incisors and patients who had orthodontic treatment were not included in the study.

Although the crown height of the central teeth was longer than the lateral teeth, no significant difference was found between the root lengths. In relation to this, it was observed that the root-crown ratio of the lateral teeth was higher than the central teeth. Results were consistent with the literature [28,29]. Similar results had obtained in the studies of Haghanifar et al. [18] in the Iranian population and Hölttä et al. [14] in the Caucasian population. In previous studies, it is seen that multi-root teeth were also included in the study [14,18]. However, both occlusal reference determination and root length determination in multi-root teeth are quite difficult. In addition, depending on age, apex formation may continue. For this reason, multi-root teeth were not included in the present study.

Lähdesmäki et al. [30] reported that the root length was longer in males compared to females in their study on individuals with XYY chromosomes, and that the Y chromosome had an effect on tooth development. Hölttä et al. [14] reported that the root-crown ratio of a group of teeth including maxillary incisors was higher in males in Caucasian populations. But, in a similar study that investigated Iranian patients, crown-root ratios is not found affected on gender [18]. In this study, both root lengths and crown height were found to be higher in males than females.

Forensic dentists can assist other specialists in determining gender using tooth and skull features [11]. Various radiographic examinations and morphological characteristics of teeth are used in determination of age and gender in forensic cases. Considering the results obtained from this study, although longer crowns and root lengths were detected in males in terms of gender, it is thought that this situation alone will not be sufficient for age and sex determination and it is needed to evaluate together with other findings.

#### 5. CONCLUSION

The root length of the teeth is especially important for the planned treatments after dental trauma in the anterior region. When radiographic devices are not accessible or x-ray images

cannot be taken due to patient-related factors, knowing the average root-crown ratio of the population provides convenience for dentists. This study can serve as a guide for the average root-crown ratio of upper incisors in Turkish population.

## DISCLAIMER

The products used for this research are commonly and predominantly use products in our area of research and country. There is absolutely no conflict of interest between the authors and producers of the products because we do not intend to use these products as an avenue for any litigation but for the advancement of knowledge. Also, the research was not funded by the producing company rather it was funded by personal efforts of the authors.

## CONSENT

All authors declare that written informed consent was obtained from the patients' parents prior to any radiograph or intra/extra-oral examination. However, informed consent according to Helsinki declaration, including all amendments and revisions, had been obtained before each standard examination.

## ETHICAL APPROVAL

As per international standard or university standard written ethical approval has been collected and preserved by the author(s).

## COMPETING INTERESTS

Authors have declared that no competing interests exist.

## REFERENCES

1. Kargul B, Çağlar E, Tanboga I. Dental trauma in Turkish children, Istanbul. Dent Traumatol. 2003;19(2):72-5.  
DOI: 10.1034/j.1600-9657.2003.00091.x  
PMID: 12656836.
2. Lauridsen E, Hermann NV, Gerds TA, Ahrensburg SS, Kreiborg S, Andreasen JO. Combination injuries 1. The risk of pulp necrosis in permanent teeth with concussion injuries and concomitant crown fractures. Dent Traumatol. 2012;28(5):364-70.

3. Trushkowsky RD. Restoration of endodontically treated teeth: Criteria and technique considerations. Quintessence Int. 2014;45(7):557-67.  
DOI: 10.1111/j.1600-9657.2011.01102.x  
DOI: 10.3290/j.qi.a31964  
PMID: 24847494.
4. Taithongchai R, Sookkorn K, Killiany DM. Facial and dentoalveolar structure and the prediction of apical root shortening. Am J Orthod Dentofacial Orthop. 1996;110(3):296-302.  
DOI: 10.1016/s0889-5406(96)80014-x  
PMID: 8814031.
5. Ricucci D, Langeland K. Apical limit of root canal instrumentation and obturation, part 2. A histological study. Int Endod J. 1998;31(6):394-409.  
DOI: 10.1046/j.1365-2591.1998.00183.x  
PMID: 15551607.
6. Çelik K, Belli S. Failure cases in root canal therapies. EÜ Dişhek Fak Derg. 2012;33(1):6-12.
7. Sjogren U, Hagglund B, Sundqvist G, Wing K. Factors affecting the long-term results of endodontic treatment. J Endod. 1990;16(10):498-504.  
DOI: 10.1016/S0099-2399(07)80180-4  
PMID: 2084204.
8. Yücel A, Özsezer E. Endodontic root canal working length determination methods. Ondokuz Mayıs Univ Dis Hekim Fak Derg. 2004;5(3):161-167.
9. Lopatiene K, Dumbravaite A. Risk factors of root resorption after orthodontic treatment. Stomatologija. 2008;10(3):89-95.  
PMID: 19001842.
10. Travess H, Roberts-Harry D, Sandy J. Orthodontics. Part 6: Risks in orthodontic treatment. Br Dent J. 2004;196(2):71-7.  
DOI: 10.1038/sj.bdj.4810891  
PMID: 14739957.
11. Nagare SP, Chaudhari RS, Birangane RS, Parkarwar PC. Sex determination in forensic identification, a review. J Forensic Dent Sci. 2018;10(2):61-66.  
DOI: 10.4103/jfo.jfds\_55\_17

- PMID: 30745778;  
 PMCID: PMC6344795.
12. Mohammed F, Fairozekhan AT, Bhat S, Menezes RG. Forensic odontology. In StatPearls. StatPearls Publishing; 2020. PMID: 31082028.
  13. Yun HJ, Jeong JS, Pang NS, Kwon IK, Jung BY. Radiographic assessment of clinical root-crown ratios of permanent teeth in a healthy Korean population. *J Adv Prosthodont.* 2014;6(3):171-6. DOI: 10.4047/jap.2014.6.3.171 Epub 2014 Jun 24. PMID: 25006380; PMCID: PMC4085240.
  14. Hölttä P, Nyström M, Evälahti M, Alaluusua S. Root-crown ratios of permanent teeth in a healthy Finnish population assessed from panoramic radiographs. *Eur J Orthod.* 2004;26(5):491-7. DOI: 10.1093/ejo/26.5.491. PMID: 15536837.
  15. Brook AH, Holt RD. The relationship of crown length to root length in permanent maxillary central incisors. *Proc Br Paedod Soc.* 1978;8:17-20. PMID: 290983.
  16. Stramotas S, Geenty JP, Darendeliler MA, Byloff F, Berger J, Petocz P. The reliability of crown-root ratio, linear and angular measurements on panoramic radiographs. *Clin Orthod Res.* 2000;3(4):182-191. DOI: 10.1034/j.1600-0544.2000.030404.x PMID: 11553073.
  17. Choi SH, Kim JS, Kim CS, Yu HS, Hwang CJ. Cone-beam computed tomography for the assessment of root-crown ratios of the maxillary and mandibular incisors in a Korean population. *Korean J Orthod.* 2017;47(1):39-49. DOI: 10.4041/kjod.2017.47.1.39 Epub 2016 Dec 19. PMID: 28127538; PMCID: PMC5266124.
  18. Haghanifar S, Moudi E, Abbasi S, Bijani A, Poorsattar Bejeh Mir A, Ghasemi N. Root-crown ratio in permanent dentition using panoramic radiography in a selected Iranian population. *J Dent (Shiraz).* 2014;15(4):173-9. PMID: 25469356; PMCID: PMC4247840.
  19. Wang J, Rousso C, Christensen BI, Li P, Kau CH, MacDougall M, Lamani E. Ethnic differences in the root to crown ratios of the permanent dentition. *Orthod Craniofac Res.* 2019;22(2):99-104. DOI: 10.1111/ocr.12288. Epub 2019 Feb 8. PMID: 30650237; PMCID: PMC6449179.
  20. Cronin RJ, Wardle WL. Prosthodontic management of vertical root extrusion. *J Prosthet Dent.* 1981;46(5):498-504. DOI: 10.1016/0022-3913(81)90236-5 PMID: 7028967.
  21. Koyuturk AE, Malkoc S. Orthodontic extrusion of subgingivally fractured incisor before restoration. A case report: 3-years follow-up. *Dent Traumatol.* 2005;21(3):174-8. DOI: 10.1111/j.1600-9657.2005.00291.x PMID: 15876331.
  22. Stramotas S, Geenty JP, Petocz P, Darendeliler MA. Accuracy of linear and angular measurements on panoramic radiographs taken at various positions in vitro. *Eur J Orthod.* 2002;24(1):43-52. DOI: 10.1093/ejo/24.1.43 PMID: 11887378.
  23. White SC, Pharoah MJ. White and pharoah's oral radiology e-book: Principles and interpretation: Elsevier health sciences. 2018:151.
  24. Ezoddini AF, Sheikhha MH, Ahmadi H. Prevalence of dental developmental anomalies: A radiographic study. *Community Dent Health.* 2007;24(3):140-4. PMID: 17958073.
  25. Näsman M, Forsberg CM, Dahllöf G. Long-term dental development in children after treatment for malignant disease. *Eur J Orthod.* 1997;19(2):151-9. DOI: 10.1093/ejo/19.2.151 PMID: 9183064.

26. de Moraes ME, de Moraes LC, Dotto GN, Dotto PP, dos Santos LR. Dental anomalies in patients with Down syndrome. *Braz Dent J.* 2007;18(4):346-50.  
DOI: 10.1590/s0103-64402007000400014  
PMID: 18278307.
27. Bajaj N, Madan N, Rathnam A. Cessation in root development: Ramifications of 'Stevens-Johnson' syndrome. *J Indian Soc Pedod Prev Dent.* 2012;30(3):267-70.  
DOI: 10.4103/0970-4388.105023
28. Nelson SJ. *Wheeler's dental anatomy, physiology and occlusion-e-book*: Elsevier Health Sciences. 2014;97.
29. Phulari RG. *Textbook of dental anatomy, physiology and occlusion*: JP Medical Ltd. 2013;119.
30. Lähdesmäki R, Alvesalo L. Root lengths in 47,XYY males' permanent teeth. *J Dent Res.* 2004;83(10):771-5.  
DOI: 10.1177/154405910408301007  
PMID: 15381717.

© 2021 Ozmen et al.; This is an Open Access article distributed under the terms of the Creative Commons Attribution License (<http://creativecommons.org/licenses/by/4.0>), which permits unrestricted use, distribution, and reproduction in any medium, provided the original work is properly cited.

*Peer-review history:*  
*The peer review history for this paper can be accessed here:*  
<http://www.sdiarticle4.com/review-history/67708>