



# Recurrent Spontaneous Pneumothorax Revealing Marfan Syndrome: A Case Report

Hanane Benjelloun <sup>a++</sup>, Safia Rachid <sup>a</sup>, Asmaa Rattal <sup>a\*</sup>,  
Hanaa Harraz <sup>a++</sup>, Nahid Zaghba <sup>a++</sup>, Khadija Chaanoun <sup>a++</sup>  
and Najiba Yassine <sup>a++</sup>

<sup>a</sup> Department of Pulmonology, CHU Ibn Rochd Casablanca, Morocco.

## Authors' contributions

This work was carried out in collaboration among all authors. All authors read and approved the final manuscript.

## Article Information

DOI: <https://doi.org/10.9734/jammr/2024/v36i65471>

## Open Peer Review History:

This journal follows the Advanced Open Peer Review policy. Identity of the Reviewers, Editor(s) and additional Reviewers, peer review comments, different versions of the manuscript, comments of the editors, etc are available here: <https://www.sdiarticle5.com/review-history/118399>

Case Study

Received: 01/04/2024  
Accepted: 06/06/2024  
Published: 07/06/2024

## ABSTRACT

The present study reports about recurrent spontaneous pneumothorax revealing Marfan syndrome. Marfan syndrome is a rare autosomal dominant disease that affects connective tissue and affects several organs, including the lung. It appears at a variable age and can be unrefined. This is a case of patient aged 16 years, eldest of two siblings, without toxic habits, treated for pulmonary tuberculosis confirmed bacteriologically 2 years ago and operated on 5 years ago for a left inguino-scrotal hernia. The patient presented to the department on day 7 after discharge following spontaneous stabbing left chest pain associated with dyspnea at the slightest effort. On clinical examination, there was a syndrome of air effusion in the left hemithorax. The frontal chest X-ray

<sup>++</sup> Professor;

\*Corresponding author: E-mail: [Asmaarattal45@gmail.com](mailto:Asmaarattal45@gmail.com);

**Cite as:** Benjelloun, Hanane, Safia Rachid, Asmaa Rattal, Hanaa Harraz, Nahid Zaghba, Khadija Chaanoun, and Najiba Yassine. 2024. "Recurrent Spontaneous Pneumothorax Revealing Marfan Syndrome: A Case Report". *Journal of Advances in Medicine and Medical Research* 36 (6):291-96. <https://doi.org/10.9734/jammr/2024/v36i65471>.

revealed a large total left pneumothorax which was drained. Lung involvement rarely modifies the respiratory functional prognosis. The occurrence of a pneumothorax is rarely a mode of entry into the disease, hence the interest in discussing the diagnosis in cases of recurrent spontaneous pneumothorax or thoracic deformation.

**Keywords:** *Pneumothorax; chest X-ray; pulmonary tuberculosis; Marfan syndrome; aortic dilatation.*

## 1. INTRODUCTION

Marfan syndrome is a rare autosomal dominant disease that affects connective tissue and affects several organs, including the lung [1-3]. It appears at a variable age and can be unrefined. The diagnosis is made on a combination of clinical, paraclinical and sometimes evolving arguments. The occurrence of a pneumothorax is rarely a mode of entry into the disease.

## 2. CASE PRESENTATION

This is a patient aged 16 years, eldest of two siblings, without toxic habits, treated for pulmonary tuberculosis confirmed bacteriologically 2 years ago and operated on 5 years ago for a left inguino-scrotal hernia. He was admitted for sudden, spontaneous stabbing left chest pain blocking inspiration without any notion of trauma. On admission, the patient desaturated to SpO<sub>2</sub> = 90% on room air. He was tachycardic at 110 bpm and polypneic at 22 cycles/min with signs of respiratory struggle. Examination of the thorax revealed a moderate pectus excavatum (Fig. 1A) as well as an air effusion syndrome at the level of the outer 1/3 of the left hemithorax.

On skeletal examination, the patient had a slender morphotype with a height of 1.86 m and a weight of 57 kg, so a BMI of 16.5 kg/m<sup>2</sup>. The wingspan/height ratio was 0.96 (<1.05), the thumb and wrist signs were positive (Fig. 1C, 1D), the feet were flat (Fig. 1B) and the fingers were thin and long (arachnodactyly). He had a long, narrow face with enophthalmos, downward-facing eyelid fissures, and prognathism (Fig. 1E). A clinical picture in favor of Marfan syndrome.

The chest x-ray on admission (Fig. 2A) revealed a large total left pneumothorax with some finely rimmed lumens, infiltrates on the right as well as a scoliotic attitude.

The patient received chest drainage at the level of the 5th left intercostal space on the middle axillary line with the lung returning to the wall

after 5 days, then the drain was removed after a 48-hour clamping test without incident.

A chest CT and spirometry were scheduled remotely and the alpha-1-antitrypsin dosage was normal.

The patient presented to the department on day 7 after discharge following spontaneous stabbing left chest pain associated with dyspnea at the slightest effort. On clinical examination, there was a syndrome of air effusion in the left hemithorax. The frontal chest X-ray revealed a large total left pneumothorax which was drained.

The file was discussed for surgical talcage except that the patient had presented during the same hospitalization a contralateral pneumothorax which was also drained (Fig. 2B,C) then he was transferred to the thoracic surgery department where he was operated on the left side by Wedge resection of the apex removing emphysema bubbles with a left pleurectomy under uniportal VATS. On pathological study, the lungs were emphysematous with chronic non-specific pachypleuritis without signs of malignancy.

The evolution 2 days after his discharge was marked by a recurrence of the right pneumothorax (Fig. 2D) motivating a surgical revision on the right side using the same technique.

After stabilization of the patient, an assessment was requested to look for others suffering from Marfan syndrome.

Ophthalmological examination was normal in both eyes. On cardiac evaluation, the electrocardiogram was normal and the echocardiography showed a non-dilated, non-hypertrophied LV, the site of septal dyskinesia with an LVEF of 45-50%. The tricuspid valve was the site of minimal aortic insufficiency without stenosis. The mitral valve was normal, the right cavities not dilated. The ascending aorta was dilated (sinus = 41mm ST junction = 38mm ascending aorta = 40mm). The IVC was

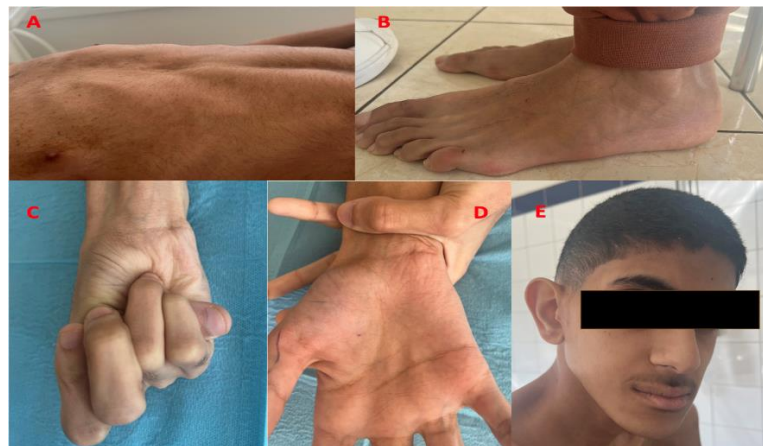compliant and not dilated and the pericardium was dry. A chest CT angiogram (Fig. 2E) was performed showing the sinus of valsalva dilated to 39mm, the sinotubal junction to 28mm, the arch of the aorta to 23mm and the descending aorta to 23mm. The z-score calculated using the Campens method was 3.78 (>2), and it was 2.83 (>2) using the Gautier method.

On the parenchymal scan sections (Fig. 2F), we noted foci of central and peripheral bronchiectasis, a mosaic appearance as well as reticulo-micronodular infiltrates of fowlers.

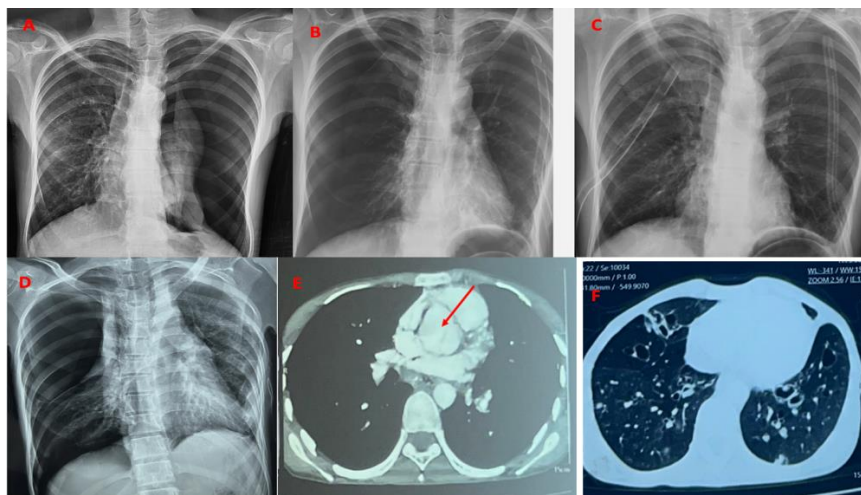
According to the diagnostic criteria for Marfan syndrome revised in 2010 by Loeys et al, the

patient had no known family history, the z-score for ascending aortic dilation was >2, and he had a systemic score to 9 (>7). The diagnosis was that of a bilateral and recurrent pneumothorax revealing classic Marfan syndrome.

After consultation with the cardiologists, there was no urgency to start beta-blockers as a preventative measure, close cardiac monitoring was proposed. Annual ophthalmological monitoring is planned. Vitamin D supplementation as well as anti-flu, anti-pneumococcal and anti-covid19 vaccinations and physiotherapy were prescribed.



**Fig. 1. Skeletal anomalies. A: Moderate pectus excavatum B: Flat feet C: Thumb sign D: Wrist sign E: Particular facial features**



**Fig. 2. Thoracic imaging. A: Chest x-ray showing a left pneumothorax B, C: Chest x-rays showing a drained bilateral pneumothorax D: Chest x-ray showing recurrence of the right pneumothorax E: Chest CT angiogram showing dilation of the ascending aorta F: Parenchymal CT section showing dilations of bronchi, mosaic appearance and micronodular infiltrates of fowlers**

### 3. DISCUSSION

Marfan syndrome is a rare autosomal dominant genetic disorder linked to mutation of the FBN1 gene encoding fibrillin. The vital prognosis is linked to the aortic damage and the functional prognosis depends on the ophthalmic and musculoskeletal damage [4].

The prevalence is estimated between 1 and 3 people per 10,000. This prevalence remains underestimated given the variability of symptoms and the presence of de novo mutations in 25% of cases. The incidence does not reveal any gender preference or ethnic origin. Life expectancy has increased by 30 years and is getting closer to that of the non-sick population thanks to advances in diagnostic and monitoring means. [5,6]

The syndrome was described in 1896 by the pediatrician Antonio-Bernard Jean Marfan. In 1914, Boerger added ectopia lens to the description. In 1931, Henricus Weve highlighted the autosomal dominant character. In 1938, Marfan published a memoir on 150 observations of dolichostenomelia, defining "Marfan syndrome" [7]

The diagnostic criteria were first developed in 1986 "Berlin classification". Then in 1996, these criteria were revised by De Paepe et al, proposing a new classification: The Ghent criteria. The latter were revised by Loeys et al in 2010 with two scenarios depending on the presence or absence of a family history of Marfan syndrome [4].

Paraclinical investigations essential to the diagnosis include echocardiography, an ECG, imaging of the aorta by CT angiography or MRI, a complete ophthalmological examination, an X-ray of the entire spine and genetic study by searching for the FBN1 (Ch15) gene. Optional tests are a wrist x-ray to assess bone age and a lumbar MRI [4]

The association of spontaneous pneumothorax and Marfan was studied through two series in 1984 [8]. The first included 100 patients where the frequency of pneumothorax was 11% and the second of 249 patients where the frequency was 4.4%, including 5 recurrences and 2 bilateral pneumothorax. More recently, the Mayo Clinic series included 166 cases where the frequency of pneumothorax was 4.8%. It was also noted that the incidence was not influenced by smoking

and that young men were more frequently affected with an average age of 21 years [9].

The increased risk of pneumothorax during Marfan syndrome is attributed to the presence of apical bullae or blebs, abnormalities of the connective tissue of the lung parenchyma and the greater mechanical stress in the apices linked to the large size of the patients. As for the histological lesions, they are no different from idiopathic spontaneous pneumothorax.

There is nothing special about the management of Marfan syndrome, but some authors suggest surgical intervention from the first episode given the high frequency of relapses after chest drainage [10].

Other respiratory manifestations are noted during Marfan syndrome. Obstructive sleep apnea hypopnea syndrome (OSAHS) is explained by the collapsibility of the larynx and associated craniofacial abnormalities [11,12].

Parenchymal abnormalities such as emphysema which is explained by the type 1 fibrillin abnormality which increases the risk of spontaneous pneumothorax [13].

Bronchiectasis is described during Marfan syndrome it is linked to the abnormality of elastin and collagen [14].

There are multiple thoracic deformities during Marfan such as pectus carinatum, kyphosis and scoliosis but pectus excavatum remains the main malformation [15-17].

Dilation of the aorta is the most serious vascular injury given the risk of aortic dissection. However, other arteries, of large or medium caliber, may be rarely affected. Exceptional cases of giant pulmonary artery aneurysms have been described. Dilatation of the pulmonary artery no longer constitutes a diagnostic criterion given the lack of specificity and the absence of reference data for the measurements [18-20].

There is no curative treatment to date. Treatment must be multidisciplinary, based primarily on prevention. The cardiac component is based on the prescription of beta-blockers, calcium channel blockers are off-label and ACE inhibitors are still under evaluation. Anticoagulants are prescribed for people with mechanical valves.

The rheumatological component includes vitamin D and calcium supplementation. Growth inhibitors such as estrogen and depot somatostatin are off-label and analgesics are used in cases of pain.

Dental care and orthodontics are important for quality of life and prevention of endocarditis. Surgical treatment can be offered, when indicated, either ophthalmological, cardiac, orthopedic or talc treatment.

Psychological support is desirable, particularly among adolescents [21,22].

#### 4. CONCLUSION

Marfan syndrome is a rare genetic connective tissue disorder. Cardiovascular damage constitutes the vital prognosis and the functional prognosis depends on the ophthalmological and musculoskeletal damage. Lung involvement rarely modifies the respiratory functional prognosis. The occurrence of a pneumothorax is rarely a mode of entry into the disease, hence the interest in discussing the diagnosis in cases of recurrent spontaneous pneumothorax or thoracic deformation.

Early medical and/or surgical treatment and monitoring improve the prognosis.

#### CONSENT

As per international standards, parental written consent has been collected and preserved by the author(s).

#### ETHICAL APPROVAL

It is not applicable.

#### COMPETING INTERESTS

Authors have declared that no competing interests exist.

#### REFERENCES

1. Jaabouti G, Bencchakroun S, Mahraoui C, Hafidi NE. Post-Traumatic Pulmonary Pneumatocoles: A Case Report. *Asian J. Med. Health.* 2023;21(9):95-100. Accessed On: 2024 May 30. Available: <https://journalajmah.com/index.php/AJMAH/article/view/862>
2. Onur B. Analysis of Patients with Emergency Thoracic Trauma. *J. Adv. Med. Pharm. Sci.* 2022;24(11-12):16-2. Accessed On : 2024 May 30 Available: <https://journaljamps.com/index.php/JAMPS/article/view/586>
3. Gottlieb M, Long B. Managing spontaneous pneumothorax. *Annals of Emergency Medicine.* 2023;81(5):568-76.
4. Ho NCY, Tran JR, Bektas A. Marfan's syndrome. *Lancet.* 2005;366:1978—81.
5. Guillermo S. Marfan syndrome and pregnancy. About 16 cases and review of the literature » Dissertation: Midwife. Nantes: University of Nantes UFR Medicine, 2016;76.
6. Chan YC, Ting CW, Ho P, Poon JT, Cheung GC, Cheng SW. Ten-year epidemiological review of in-hospital patients with Marfan syndrome. *Ann Vasc Surg.* 2008;22(5):608-12.
7. Philipon, P. Marfan syndrome Publication of the French Association of Marfan Syndrome. 2019;64.
8. Hall JR, Pyeritz RE, Dudgeon DL, Haller JA Jr. Pneumothorax in the Marfan syndrome: prevalence and therapy. *Ann Thorac Surg.* 1984;37(6):500-4.
9. Karpman C, Aughenbaugh GL, Ryu JH. Pneumothorax and bullae in Marfan syndrome. *Breathing.* 2011;82(3):219-24
10. Suzuki T, Akiba T, Miyake R, Marushima H, Morikawa T. Familial spontaneous pneumothorax in two adult siblings with Marfan syndrome. *Ann Thorac Cardiovasc Surg.* 2010;16(5):362-4.
11. Cistulli PA, Sullivan CE. Sleep apnea in Marfan's syndrome. Increased upper airway collapse during sleep. *Chest.* 1995;108(3):631-5.
12. Verbraecken J, Paelinck BP, Willemsen M, Van de Heyning P, De Backer W. Aortic root diameter and nasal intermittent positive airway pressure treatment in Marfan's syndrome. *Clin Genet.* 2003;63(2):131-4
13. Jondeau G, Detaint D, Tubach F, Arnoult F, Milleron O, Raoux F et al. Aortic event rate in the Marfan population: A cohort study. *Traffic.* 2012;125(2):226-32
14. Brinchault G, Morel V, Meunier C, Belleguic C, Delaval P. Bronchial dilatations, *EMC – Medicine.* 2004;1(2): 131-140
15. Tocchioni F, Ghionzoli M, Messineo A, Romagnoli P. Pectus excavatum and

- heritable disorders of the connective tissue. *Pediatr Rep.* 2013;5(3):e15
16. Stheneur C, Tubach F, Jouneaux M, Roy C, Benoist G, Chevallier B, et al. Study of evolution phenotype during childhood in Marfan syndrome to improve clinical recognition. *Genet Med.* 2014;16(3):246-50
  17. Kelly RE, Goretsky MJ, Obermeyer R, Kuhn MA, Redlinger R, Haney TS, et al. Twenty-one years of experience with minimally invasive repair of pectus excavatum by the Nuss procedure in 1215 patients. *Ann Surg.* 2010;252(6):1072-81.
  18. Détaint D, Faivre L, Collod-Beroud G, Child AH, Loeys BL, Binquet C, et al. Cardiovascular manifestations in men and women carrying an FBN1 mutation. *Eur Heart J.* 2010;31(18):2223-9.
  19. Awais M, Williams DM, Deeb GM, Shea MJ. Aneurysms of medium-sized arteries in Marfan syndrome. *Ann Vasc Surg.* 2013;27(8):1188.e5-7.
  20. Pati PK, George PV, Jose JV. Giant pulmonary artery aneurysm with dissection in a case of Marfan syndrome. *J Am Coll Cardiol.* 2013;61(6):685.
  21. TACQUET Hugo, MARFAN syndrome: pathophysiology, therapeutic management and role of the community pharmacist, Faculty of Pharmacy of Lille; 2021.
  22. Cistulli PA, Wilcox I, Jeremy R, Sullivan CE. Aortic root dilatation in Marfan's syndrome: a contribution from obstructive sleep apnea? *Chest.* 1997;111(6):1763-6.

© Copyright (2024): Author(s). The licensee is the journal publisher. This is an Open Access article distributed under the terms of the Creative Commons Attribution License (<http://creativecommons.org/licenses/by/4.0>), which permits unrestricted use, distribution, and reproduction in any medium, provided the original work is properly cited.

*Peer-review history:*

*The peer review history for this paper can be accessed here:*  
<https://www.sdiarticle5.com/review-history/118399>