



Supernumerary Molars: A Rare Finding

Ayesha Bashir¹, Sohail Abbas Khan², Muhammad Kashif^{3*}, Noreen Sarwar¹
and Shazia Naaz¹

¹de'Montmorency College of Dentistry, Lahore, Pakistan.

²Nishtar Institute of Dentistry, Multan, Pakistan.

³University of Health Sciences, Lahore, Pakistan.

Authors' contributions

This work was carried out in collaboration between all authors. Authors AB and SAK designed the study, authors AB, NS, MK and SN wrote the protocol and wrote the first draft of the manuscript. Authors AB and MK managed the literature searches, analyses of the study. All authors read and approved the final manuscript.

Article Information

DOI: 10.9734/BJMMR/2016/21951

Editor(s):

(1) Alex Xiucheng Fan, Department of Biochemistry and Molecular Biology, University of Florida, USA.

Reviewers:

(1) Jehona Ahmedi, University of Prishtina, Kosovo.

(2) N. B. Nagaveni, College of Dental Sciences, Davangere, Karnataka, India.

(3) Madhuri Vegesna, Dr NTR University of health sciences, India.

(4) H. Roshan D. Peiris, University of Peradeniya, Sri Lanka.

Complete Peer review History: <http://sciencedomain.org/review-history/12308>

Case Study

Received 10th September 2015

Accepted 2nd November 2015

Published 20th November 2015

ABSTRACT

Panoramic radiographs of a female patients aged twenty one years without any associated syndromic or systemic medical history, revealed the presence of the two supernumerary molars, right upper and left lower fourth molars. Both the teeth were disto-molars. The right upper fourth molar had normal tooth morphology with regard to its crown and root but was slightly smaller than the existing third molars. The left lower disto-molar had somewhat different morphology as compared to adjacent third molar and smaller in size as compared to the fourth right upper disto-molar. Their crowns were tuberculated and both had single root (2D radiographic morphology).

Keywords: Fourth molars; distomolars; paramolars; supernumerary molars; hyperdontia.

*Corresponding author: E-mail: drkashifazam@gmail.com;

1. INTRODUCTION

Hyperdontia is the condition of having supernumerary teeth, or teeth which appear in addition to the regular number of teeth [1].

Supernumerary teeth can be classified by shape and by position. The shapes include supplemental (where the tooth has a normal shape for the teeth in that series), tuberculate (also called barrel shaped) conical (also called peg lateral) compound odontome (multiple small tooth like forms) and complex odontoma (a disorganized mass of dental tissue) [2].

When classified by position, a supernumerary tooth is a mesiodens, which is a malformed, peg like tooth that occurs between the maxillary central incisors. Forth and fifth molars that form behind the third molars are another kind of supernumerary teeth. Disto-molars are supernumerary teeth that are distal to the third molars while paramolars are on the side of the molars [3].

Supernumerary teeth may be found in both the primary and secondary dentition, although they are more common in the permanent dentition. Sex dimorphism is reported by most authors, males being more commonly effected. A familial tendency has been reported in the literature. The presence of the supernumerary teeth may be a part of developmental disorders or a syndrome such as Cleft lip and palate, Cleidocranial dystoses, Gardeners syndrome, Fabry Andersons syndrome, Ellis-van Creveld (Chondroectodermal dysplasia), Ehlers Danlos syndrome, incontinentia pigmenti and tricho-rhino-phalangial syndrome [4-6].

Effects of supernumerary teeth on the developing dentition vary. There may be no effect or teeth discovered either as a chance radiographic finding or following their eruption [4].

According to dental literature, the frequency of supernumerary teeth is 1-3%. Occurrence of supernumerary teeth is not a common finding. The preferred location is in the maxilla, mostly incisors, followed by the molars. Authors agree that they occur more frequently in the maxilla than in the mandible. Few authors feel that they are found more often in the mandible than in the maxilla. Supernumerary teeth may or may not be erupted [7].

Refoua [6] in his research paper described an unusual case of 5 disto-molars on radiographic

examination (three in maxilla and two mandible). There was no associated medical history and the patient was otherwise healthy. A pericoronal radiolusency was also observed associated with the lower right third molar. The phenomenon is interesting especially considering the fact that in modern man, missing third molars are becoming a common finding [6]. The etiology of the supernumerary teeth remains unclear. Several theories have been suggested for there occurrence such as the phylogenetic theories. Phylogenetic evolution has resulted in a reduction of both the number in size of teeth and supernumerary premolars may be an atavistic appearance of the third or forth premolars of the primitive dentition [8]. Second is the dichotomy theory which stated that a supernumerary tooth is created as a result of dichotomy of the tooth or it may develop from complete splitting a tooth bud [9]. Third is a hyperactive dental lamina. A localized hyper dental lamina is an independent cause of development of the supernumerary teeth. It is suggested that supernumerary teeth may arise as a result of conditioned hyperactivity of a dental lamina and a combination of genetic and environmental factors- and unified etiologic explanation [10,11].

2. A CASE REPORT

A twenty one years old, healthy female without any associated medical or syndromic history was referred to Conservative Dentistry Department of de' Montmorency College of Dentistry Lahore, Pakistan, due to the chief complaint of pain in left lower second molar and right upper third molar.

Clinical examination was done and panoramic and periapical radiographs were advised. The left lower second molar had been managed by endodontic treatment. Extraction is advised for right upper third molar due to limitation in mouth opening and complexity of pulp root canals. Clinical and radiographic examination revealed the presence of unerupted right maxillary fourth molar and left mandibular forth molar. They were distomolars located just posterior to the right upper and left lower third molar. The right upper forth molar had normal morphology; crown and roots were significantly developed, conical in shape as third molar but smaller in size. The crown of left lower forth molar was ball shaped and root was fully developed but relatively normal crown /root ratio. It was smaller in size as compared to right upper forth molar. Both the disto-molars are unerupted and not causing any problem to the patient so they are left as such.

These all morphological findings were noted on 2D radiographic images as shown in the following figure (Fig. 1). Ideally these findings can better be noted on 3D radiographic images.

3. DISCUSSION

Many researchers have already studied about prevalence of supernumerary molars. Stafne reported a prevalence of 1%, Luten 2% and 1.95% by Backman. It is reported in the literature that fourth fifth sixth and seventh molars were seen; however fourth molar was seen most frequently [2,12]. Our findings described in this paper found two fourth molars in one case.

Stafne reported that most of the fourth molar are blunt, multicuspid and much smaller than the third molars. They may be conical or equally as large as normal molars [13]. Dubuk has reported a paramolar case of 4mm in length. It had a ball shaped crown and had relatively normal crown/root length ratio [14]. Maxillary distomolar found in the present case was conical in shape but smaller in size. Mandibular disto-molar was ball shaped, smaller in size, and its roots were not developed completely. Obtaining a complete

medical history is critical when a patient with multiple supernumerary teeth is to be treated. In order to consider multiple supernumeraries in a patient, associated conditions like cleft lip with or without palate and syndromes such as cleidocranial dysplasia and Gardner's Syndrome should be ruled out [15]. Supernumerary teeth may erupt normally, remain impacted, appear inverted or assume an ectopic position or an abnormal path of eruption. Their development might precipitate a variety of complications such as crowding, delayed eruption, development of diastema, cystic lesions such as dentigerous cysts and resorption or rotation of adjacent teeth. Therefore early diagnosis, proper evaluation and appropriate treatment are essential [16].

Treatment options for impacted teeth include observation, intervention relocation and extraction. On occasion, there may be some overlap between these treatment options. Appropriate and thorough radiographic examination, especially in mandibular third molar, is essential for correct diagnosis and management of multiple supernumerary teeth [16].

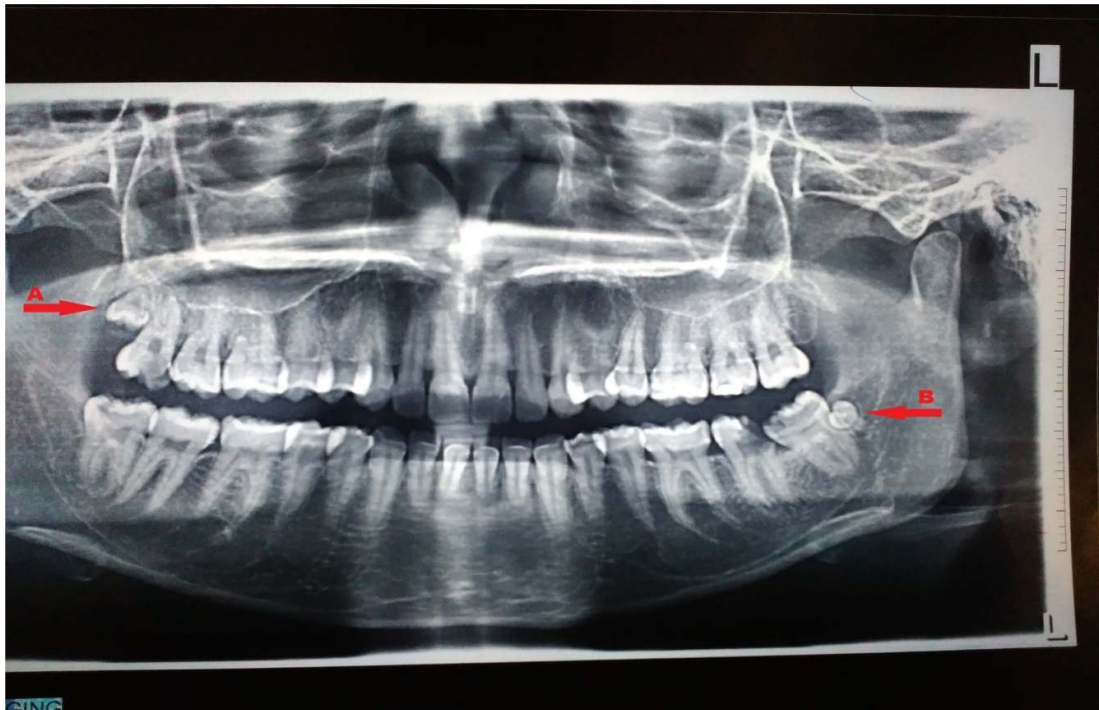


Fig. 1. Panoramic radiograph showing impacted right maxillary (arrow A) and left mandibular disto-molars (arrow B)

Authors have discussed the effects of supernumerary teeth in occlusion [17]. Our patient had presented with two distomolars without any relevant disease and dental complications such as crowding, delayed eruption, development of a diastema, cystic lesions and such as dentigerous cysts and resorption or rotation of adjacent teeth. Number of cases had been presented where distomolars had caused malocclusion [2]. Thus such patients should be referred for orthodontic assessment and further treatment to correct their dental malocclusion, to improve the aesthetic and functional problems. Long term monitoring and followup is very important when dealing with paediatric dental patients [18].

4. CONCLUSION

The distomolar is not very common finding but an interesting dental anomaly that a dentist may find by chance. It may also be a clue to some underlying syndromic problem. Therefore awareness of its incidence and behaviour is significant.

CONSENT

All authors declare that 'written informed consent was obtained from the patient (or other approved parties) for publication of this case report and accompanying images.

ETHICAL APPROVAL

All authors hereby declare that all experiments have been examined and approved by the appropriate ethics committee and have therefore been performed in accordance with the ethical standards laid down in the 1964 Declaration of Helsinki.

COMPETING INTERESTS

Authors have declared that no competing interests exist.

REFERENCES

1. Wikipedia. Supernumerary teeth; 2011.
2. Kokten G, Balcioglu H, Buyukertan M. Supernumerary fourth and fifth molars: A report of two cases. *Journal of Contemporary Dental Practice*. 2003;4(4): 67-76.
3. Nagaveni NB, Umashankara KV, Radhika NB, Satisha TS. Multiple impactions in Non-syndromic patient: A case report. *Archives of Orofacial Sciences*. 2011;6(2): 33-8.
4. Puri K, Bansal M, Jain D, et al. Nonsyndromic multiple supernumerary premolars and paramolars: An overview and report of 2 cases. *Indian Journal of Dental Sciences*. 2013;5(5):54-6.
5. Marya CM, Kumar BRA. Familial occurrence of mesiodents with unusual findings: Case reports. *Quintessence Int*. 1998;29:49-51.
6. Refoua Y, Arshad M. An unusual case of bilateral maxillary and mandibular supernumerary teeth: A case report. *J Dent Tehran*. 2006;3:140-2.
7. Mallineni SK. Supernumerary teeth: Review of the literature with recent updates. *Conference Papers in Science*. 2014;2014:1-6.
8. Smith JD. Hyperdontia: A case report. *J Am Dent Assoc* 1969;79:1191-2.
9. Nayak G, Shetty S, Inderpreet S, Pitalia D. Paramolars- A supernumerary molar: A case report and overview. *Dental Research Journal*. 2012;9:797-803.
10. Thumati P, David CM, Tiwari R. Non-syndromic multiple supernumerary teeth: A case report and review of literature. *IJSS Case Reports & Reviews*. 2014;1(5):1-5.
11. Khanduri N, Gupta B, Kaul B, Sasan NS. Surgical removal of a mesiodens in a 8 years old male. *International Journal of Clinical Cases and Investigations* 2015; 6(4):125-130.
12. Nagaveni NB, Umashankara KV, Radhika NB, Praveen Reddy B, Manjunath S. Maxillary paramolar: Report of a case and literature review. *Archives of Orofacial Sciences*. 2010;5(1):24-8.
13. Stafne EC. Supernumerary teeth. *Dent Cosmos*. 1935;74:653-9
14. Dubk AN, Selvig K, Tellefsen G, et al. Atypically located paramolar: Report of a rare case. *Eur J Oral Sci* 1996;104(20): 138-40
15. Batra P, Duggal R, Prakash H. Non syndromic multiple supernumerary teeth transmitted as an autosomal dominant trait. *J Oral Pathol Med*. 2005;34(10): 621-5.

16. Ramsaran AS, Barclay S, Scipioe, Ogunsalu C. Non syndromal multiple buried supernumerary teeth: Report of two cases from the English speaking Caribbean and a review of the literature. West Indian Med J. 2005;54(5):334-6.
17. Goaz-White Oral Radiology. 2nd. NY: The CV Mosby Co; 1987.
18. Fazliahsn. Supernumerary tooth; Report of a case. Archives of Orofacial Sciences. 2007;2:54-8.

© 2016 Bashir et al.; This is an Open Access article distributed under the terms of the Creative Commons Attribution License (<http://creativecommons.org/licenses/by/4.0>), which permits unrestricted use, distribution, and reproduction in any medium, provided the original work is properly cited.

Peer-review history:
The peer review history for this paper can be accessed here:
<http://sciencedomain.org/review-history/12308>