



Research Article

The Effect of Astragaloside IV on Isoproterenol-Induced Myocardial Infarction in Rats

Fatemeh Fathiazad¹, Nezhla Tamarzadeh², Doa Alsos², Alireza Garjani², Haleh Vaez^{2*}

¹Department of Pharmacognosy, Faculty of Pharmacy, Tabriz University of Medical Sciences, Tabriz, Iran.

²Department of Pharmacology and Toxicology, Faculty of Pharmacy, Tabriz University of Medical Sciences, Tabriz, Iran.

Article Info

Article History:

Received: 13 September 2018

Revised: 28 November 2018

Accepted: 1 December 2018

ePublished: 30 June 2019

Keywords:

- Astragaloside IV
- Myocardial infarction
- Isoproterenol
- Oxidative stress
- Isolated heart

ABSTRACT

Background: Astragaloside IV (AST) is a saponin from the roots of *Astragalus* plants which has been widely used in traditional medicine to treat cardiovascular diseases. However, the effect of AST on myocardial infarction remains unknown. Thus, we aimed to investigate the cardio protective effects of AST on isoproterenol-induced myocardial infarction in rats.

Methods: AST was isolated from the roots of *Astragalus caspicus*. Male Wistar rats were assigned to 5 groups of control, isoproterenol, and treatment with 2.5, 5 and 10 mg/kg AST given orally immediately before MI induction. Subcutaneous injection of isoproterenol (100 mg/kg) for two consecutive days was used to induce myocardial infarction. AST was given orally once daily for 4 days. On the fifth day hemodynamic and electrocardiographic parameters were assessed, and serum and tissue samples were used to evaluate histological and biochemical changes. To more assessment of the effects of AST on myocardium, we also used three doses of 0.1, 1 and 2 μ M of AST in isolated heart model. In statistical analysis with one-way-ANOVA test, any differences between groups were considered significant at $p < 0.05$.

Results: Isoproterenol injection caused ECG abnormality, hemodynamic depression and myocardium damage. While AST administration increased mean arterial blood pressure and heart rate and improved the left ventricular contractility. The peripheral neutrophil count, cardiac enlargement and cardiac ischemia was significantly decreased by AST. Also, histopathological evaluations showed that AST significantly diminished post MI necrosis and fibrosis in heart tissue and inhibited the inflammatory responses. The isolated heart studies hemodynamic factors showed no significant changes.

Conclusion: Results showed that AST can protect heart against myocardial infarction by improving cardiac histology and ventricular contractility. Due to the lack of protection in the isolated heart, it is likely that the positive effects are more associated with the improvement of the oxidative stress markers in the systemic circulation, and the absolute effect on the isolated heart does not play an essential role in myocardium protection.

Introduction

Myocardial infarction (MI) is one of the most widely spread manifestations of cardiovascular disease, which is associated with a disparity between coronary blood supply and myocardial demand. According to the world health organization report, heart disease and stroke will become the leading causes of death and disability worldwide by the year 2020.¹ Furthermore, MI can also cause other obvious symptoms, such as myocardial fibrosis and cardiac hypertrophy.²

After acute coronary artery occlusion, the blood flow from the obstruction point is cut off, and the defective region of myocardium is infarcted and cannot continue to function and may lead to arrhythmias. Heart damage caused by myocardial infarction begins with the production of free radicals and active oxygen species,

which act as a chemotactic factor to cause neutrophils entry to damaged tissue and exacerbate injuries. Neutrophils produce more oxygenated radicals and enzymes such as elastase that causes more damage.³ Therefore, one of the treatment options for limiting injury in ischemia-reperfusion is free radical scavenging.

The rat model of isoproterenol-induced myocardial infarction is a non-invasive standardized method to evaluate protective effect of various potential compounds against MI. Subcutaneous injection of isoproterenol as a non-selective β -adrenergic agonist induces severe stress in myocardium, ischemic injury, myocardial hypertrophy and fibrosis.²

Studies have indicated the importance of various natural products, especially the ones with antioxidant properties, in management of numerous diseases.⁴ Several

*Corresponding Author: Haleh Vaez, E-mail: haleh.vaez@gmail.com

biochemical reactions in our body produce free radicals and active oxygen species that can damage vital biomolecules such as proteins and DNA. Natural products with antioxidant and anti-inflammatory effects play a major role in treating cardiovascular diseases.⁵ Many plants or their compounds show beneficial effects in myocardial infarction by limiting hyperlipidemia and scavenging free radicals.⁶

Astragalus (Fabaceae Family) commonly known as 'milk-vetch' or 'locoweed' is used in traditional medicine as a remedy for a wide spectrum of diseases including nephritis, diabetes mellitus and hypertension. Astragaloside IV, a saponin of cycloartane-type triterpene isolated from the roots of *Astragalus caspicus* has been shown to possess many pharmacological properties such as antimicrobial, anti-inflammatory and diuretic effects.⁷ AST also demonstrated a cardio-protective effect by increasing coronary blood flow through adjusting nitric oxide and increasing myocardial antioxidative enzymes.⁸ In animal model of heart failure, the protective effects of AST were also documented.^{9,10} Furthermore, in an isoproterenol-induced myocardial hypertrophy, the cardioprotection role of AST with relation to inhibiting the TLR4/NF- κ B signaling pathway and the attenuating inflammatory effect was indicated.¹¹ The purpose of the present study is evaluating the cardio-protective effects of AST in myocardial infarction and its efficacy in preventing the post MI injuries. Furthermore, to assess the hemodynamic effects of AST in condition of far from systemic circulation, the isolated heart method were utilized.

Materials and Method

Preparation of Astragaloside IV

Astragalus caspicus roots were collected from Tabriz, Iran in June 2016. Dried roots of *Astragalus caspicus* were used to isolate Astragaloside IV with chromatographic methods according to Fathiazad et al.¹² The collected white powder of Astragaloside IV were used for further pharmacological studies.

Animals

Male albino Wistar rats (270-310 g) were used in this study. Rats were housed at constant temperature ($20\pm 1.8^{\circ}\text{C}$) and relative humidity ($50\pm 10\%$) in standard polypropylene cages, five per cage, under a 12 h light/dark cycle, and were allowed food and water freely. This study was performed in accordance with the Guide for the Care and Use of Laboratory Animals of Tabriz University of Medical Sciences, Tabriz-Iran (National Institutes of Health publication No 85-23, revised 1985) and approved by ethics committee of Tabriz University of Medical Sciences (ethical code: IR.TBZMED.VCR.REC.1396.1224).

In-vivo studies

Animals were randomly consigned to 5 groups of isoproterenol, control, and treatment with 2.5, 5 and 10 mg/kg of AST. Myocardial infarction was induced by

subcutaneous injection of 100mg/kg isoproterenol in normal saline solution in rats of isoproterenol and treatment groups for first two consecutive days. Treatment groups were given oral AST suspension in normal saline consecutively for 4 days; while control and isoproterenol groups were received oral normal saline.

In fifth day animals were anesthetized using ketamine and xylazine mixture. Then a thorax midline incision was operated. To measure systolic blood pressure (SBP), diastolic blood pressure (DBP), mean arterial blood pressure (MAP) and heart rate (HR), the right carotid artery was cannulated with a micro tip catheter transducer (Millar instruments, INC). In order to analyze cardiac left ventricular contractility, the catheter was inserted inside the left ventricle recording maximum and minimum of developed left ventricular pressure (LVdP/dt_{max} and LVdP/dt_{min}). A Powerlab system (AD Instrument, Australia) was used to record these parameters constantly. After recording hemodynamic factors, blood samples were gathered from the hepatic vein and centrifuged (1000 rpm, 10 min, 8°C) to obtain the serum. The serum was stored in -70°C for additional studies. The hearts were dissected out and washed in cold normal saline to calculate heart weight to body weight ratio in order to gauge cardiac hypertrophy. Afterward, they were stored in -70°C for further studies.

Peripheral neutrophil counting

Prior to centrifuging venous blood samples, a small drop of fresh blood was smeared on clean lams and fixed with methanol and colored with Gimsa solution. In order to assess percent of neutrophils, white blood cells were counted in 100x zooming light microscope.

Histopathological examination

In another set of samples, isolated hearts were initially cut out and fixed in 10% buffered formalin. The heart tissues were embedded in paraffin and sectioned in 5 μm thick segments. Some of these segments were stained with Hematoxylin and Eosin (H&E) to observe the degree of necrosis and edematous in myocardium and some were stained with Gomori Trichrom in order to detect the fibrotic tissue. Another person categorized the histopathological variations as 0, 1, 2, 3 and 4 respectively for none, low, moderate, high and intensive pathologic variations.

Determination of lipid peroxidation in myocardium

Malondialdehyde (MDA) as a product of lipid peroxidation is an important indicator for assessment of oxidative stress. The following procedure was used to gauge MDA level in myocardial tissue and serum according to Satoh et al.¹³ The hearts were homogenized in a ratio of 1/10 in 1.15% (w/v) cold KCl solutions. 0.5 ml of the homogenate was mixed with 3 ml of 1% orthophosphoric acid and shaken in a 10 ml centrifuge tube. 1 ml of 60% TBA was added to the blend, shaken, and warmed for 45 minutes in a boiling water bath. After cooling, 4 ml of n-butanol was added to the tubes and

blended strongly. Then tubes were centrifuged for 15 minutes at 5000 rpm and the amount of MDA was obtained from the absorbance at 535nm spectrophotometrically against n-butanol.

Glutathione peroxidase and superoxide dismutase

Glutathione peroxidase (GPx) and Superoxide dismutase (SOD) are antioxidant enzymes that inhibit the oxidative stress and reduce size of the infarct area by decreasing the amount of post-reperfusion injuries. Quantitative assessment of GPx and SOD in heart tissue was achieved using commercially available kit (Randox, England) consistent with manufacturer's instruction.

Lactic acid

Lactic acid as a marker of ischemia was measured in serum to figure the deviations of ischemia after treatment. In order to assess lactic acid the experiment was performed using commercially available kit (Randox, England) according to instructions of the manufacturer.

In-vitro studies

Isolated heart method were performed as published previously.¹⁴ Briefly, male Wistar rats were heparinized (1000 IU/kg; i.p.) and then anesthetized with ketamine/xylasin (60 / 10 mg/kg; i.p.). When the rats didn't responded to external stimuli, the surgery for harvesting the heart was done. Harvested heart was transferred as soon as possible to a dish containing ice cold modified Krebs–Henseleit buffer (K/H) and mounted immediately to the langendorff apparatus (ML176-V Langendorff Apparatus, ADInstruments, Australia). Isolated hearts were perfused at a constant pressure (80 mmHg) with a modified K/H solution. The perfusate was gassed with carbogen (5% CO₂/95% O₂) to set the pH in 7.38-7.56 at 37°C. To measure left ventricular contractility, a latex balloon attached to a pressure transducer (MLT844 physiological pressure, ADInstruments, Australia) was inserted into the left ventricular cavity via the mitral valve after removing the atrial appendage. After stabilization period (15 min) with infusion by K/H, the K/H without or with extract (0.1, 1, and 2 μM in separate groups) was infused for whole duration of the experiment (60 min). The changes in flow rate in whole period of experiment were assessed. By the means of inserted balloon, the heart rate, the left ventricular developed pressure [LVDP: the differences of left ventricular systolic pressure (LVSP) and left ventricular end-diastolic pressure (LVEDP)], the maximum rate of left ventricular (LV) pressure increase (LVdP/dt_{max}; contraction), the maximum rate of LV pressure decline (LVdP/dt_{min}; relaxation) were measured. All parameters were continuously recorded using a Powerlab system (ADInstruments, Australia) during 60 min.

Statistical analysis

Results were expressed as mean ± SEM. One-way

ANOVA analysis of variance was applied to compare the groups. In case of significant difference, the groups were compared with the Tukey post-test. P<0.05 was regarded as statistically significant.

Results

The in-vivo studies results

The effect of Astragaloside IV on hemodynamic parameters

Analysis of hemodynamic results indicated that the systolic blood pressure (SBP) was significantly increased from 113±12 mmHg in isoproterenol group to 123±13 and 119±12 mmHg respectively with 2.5 mg/kg and 5 mg/kg of AST. Diastolic blood pressure (DBP) which was reduced to 84±16 mmHg after Isoproterenol injection, improved to 101±9, 89±7 and 90±15 mmHg respectively with 2.5, 5 and 10 mg/kg of AST. Isoproterenol lowered the heart rate (HR) from 300±18 bpm in control group to 227±23 bpm (P<0.001); but treatment with all concentrations of AST elevated HR compared to isoproterenol group. (Table 1)

Table 1. The effects of Astragaloside IV on hemodynamic parameters in rats received isoproterenol injection.

Group (n=6)	SBP (mmHg)	DBP (mmHg)	MAP (mmHg)	Heart rate (bpm)
Control	129± 12	96± 10	112± 11	300± 18
Isoproterenol (Iso)	113± 12	84± 16	96± 11	227± 23***
AST (2.5mg/kg)+Iso	123± 13	101± 9	108± 11	241± 22
AST (5mg/kg)+Iso	119± 12	89± 7	104± 16	235± 11
AST (10mg/kg)+Iso	109± 13	90± 15	101± 21	253± 26

Data are expressed as mean±SEM (n=6). AST: Astragaloside IV; SBP: systolic blood pressure; DBP: diastolic blood pressure; MAP: mean arterial blood pressure. ***p<0.001 as compared to isoproterenol group. One way ANOVA with Tukey post- test is used.

Analyzing results of left ventricular maximal and minimal rates of pressure (LV dP/dt_{max} and LV dP/dt_{min}) indicated that compared to control group, subcutaneous injection of isoproterenol exposed a decrease in LV dP/dt_{max} (P<0.001) and elevation in LV dP/dt_{min} (P<0.001). But administration of 2.5, 5 and 10 mg/kg of AST improved these parameters approximately to the standard value, as the LV dP/dt_{max} was augmented (P<0.001, P<0.01 and P<0.001 respectively) and LV dP/dt_{min} was diminished considerably (P<0.001, P<0.01 and P<0.05 respectively). (Figure 1).

The effect of Astragaloside IV on the peripheral neutrophil count

The neutrophils percentage in peripheral blood system, was considerably elevated from 8.5±1% in control group to 21±3% in isoproterenol group (p<0.001). However oral administration of AST in 2.5 mg/kg concentration reduced the neutrophil percentage to 18±1% and the doses of 5 and 10 mg/kg were able to lower the neutrophil percentage significantly to 15±2% and 14±1% respectively (p<0.05, p<0.01). (Figure 2)

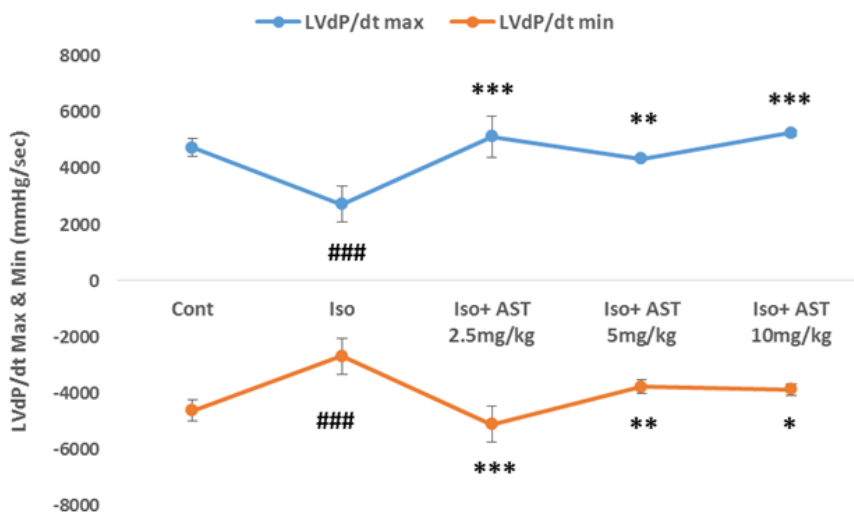


Figure 1. The effects of Astragaloside IV on left ventricular maximal and minimal rates of pressure (LV dP/dt_{max} and LV dP/dt_{min}). Cont: Control, Iso: isoproterenol; AST: Astragaloside IV. Values are expressed as mean±SEM (n=6). ^{###}p<0.001 from control group; ^{*}p<0.05, ^{**}p<0.01 and ^{***}p<0.001 as compared to isoproterenol group. One way ANOVA with Tukey test is used.

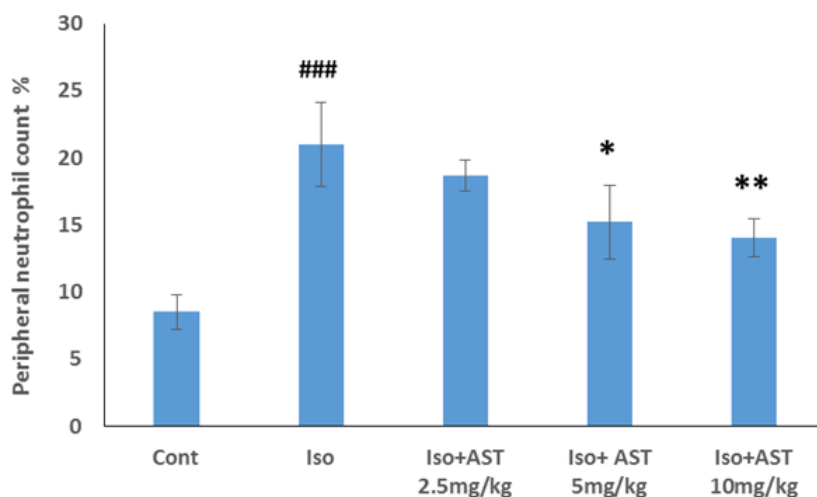


Figure 2. The effects of Astragaloside IV on peripheral neutrophil count. Iso: isoproterenol; ast: Astragaloside IV. Values are expressed as mean±SEM (n=6). ^{###}p<0.001 from control group; ^{*}p<0.05 and ^{**}p<0.01 as compared to isoproterenol group. One way ANOVA with Tukey test is used.

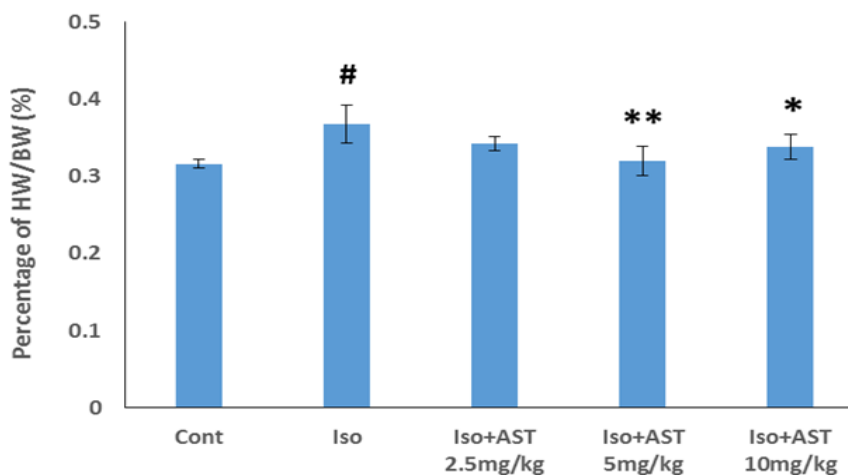


Figure 3. The effects of Astragaloside IV on wet heart weight to body weight ratio (g/g %). Iso: isoproterenol; ast: Astragaloside IV. Values are expressed as mean±SEM (n=6). [#]p<0.05 from control group; ^{*}p<0.05 and ^{**}p<0.01 as compared to isoproterenol group. One way ANOVA with Tukey test is used.

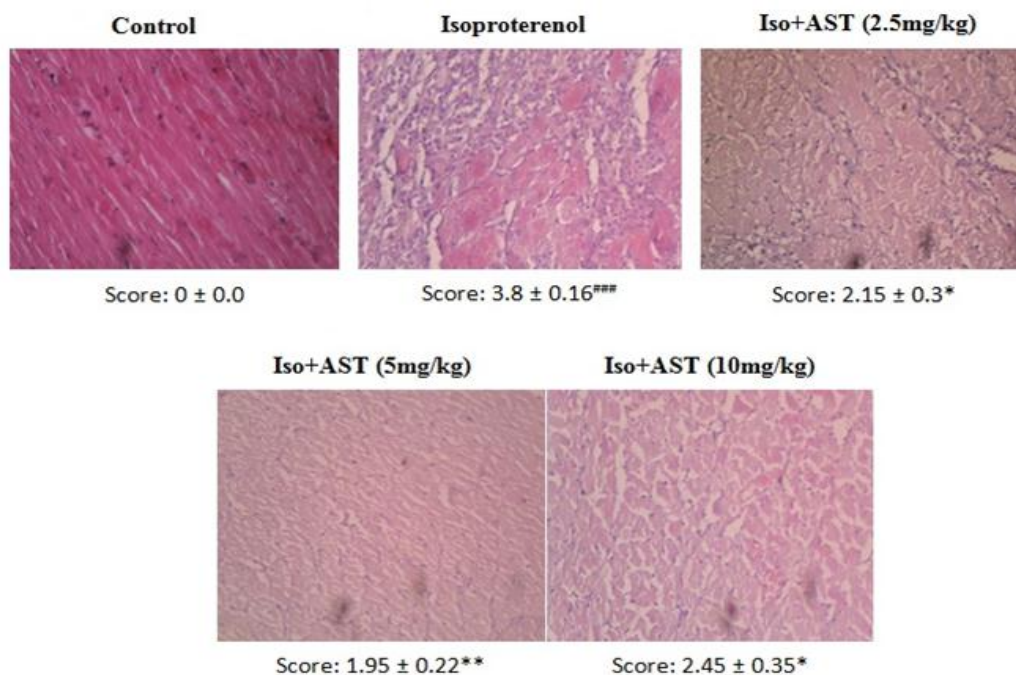


Figure 4. Photomicrographs of sections of the apex of rat heart stained with H&E. Iso: isoproterenol; AST: Astragaloside IV. H&E (40 M). Grades of 0,1,2,3 and 4 respectively show none, low, moderate, high and intensive pathologic changes. Values are expressed as mean±SEM (n=6). ***p<0.001 from control group; *p<0.05, **p<0.01 as compared to isoproterenol group. One way ANOVA with Tukey test is use.

The effect of Astragaloside IV on wet heart weight to body weight ratio (g/g %)

As it is evident in Figure 3, wet heart weight to body weight ratio (g/g %) was measured to express the degree of cardiac enlargement after heart failure. Compared to control group, the rats that received a subcutaneous injection of isoproterenol had a remarkable increase in wet heart weight to body weight ratio (p<0.05). Nevertheless treatment with 5 and 10 mg/kg AST lowered the ratio significantly to 0.31±0.01% and 0.33±0.01% respectively (p<0.001, p<0.05).

The effects of Astragaloside IV on histological changes

In order to evaluate the extent of myocardial necrosis, heart sections stained with Hematoxylin and Eosin (H&E) were examined with light microscope. The histological studies showed an intact myocardium without degeneration, necrosis and edema in control group. As it is obvious in Figure 4, tissue sections from isoproterenol treated rats exhibited a remarkable level of necrosis with intramuscular edematous and hyperplasia (p<0.001), while treatment with all doses of AST prevented the necrosis and edematous noticeably (p<0.05, p<0.01 and p<0.05 respectively).

Also myocardial sections stained with Gomeri Trichrome were examined to evaluate cardiac fibrosis after inducing MI. As indicated in Figure 5, in comparison with control group that shows no sign of degeneration and fibrosis, injection of isoproterenol lead to a severe level of fibrosis detectable as blue dyed parts (p<0.001), however treatment with 2.5 and 5mg/kg AST inhibited the

inflammatory responses and fibrosis significantly (p<0.05, p<0.01).

The effect of Astragaloside IV on MI biomarkers

MDA level in serum and myocardium was measured as an indicator of lipid peroxidation. Injection of isoproterenol caused an elevation in serum (p<0.05) and myocardial MDA (Table 2). Treatment with 2.5mg/kg AST decreased MDA level in serum (p<0.05); however administration of the other concentrations of AST had no significant effect on MDA level in serum and myocardial tissue.

Table 2. The effects of Astragaloside IV on serum and myocardial malondialdehyde (MDA) levels.

Group (n=6)	Serum (nmol/ml)	Myocardium (nmol/mg pr)
Control	1.68± 0.08	0.035± 0.01
Isoproterenol (Iso)	2.12± .0.41#	0.045± 0.019
AST (2.5 mg/kg)+Iso	1.63± 0.25*	0.065± 0.007
AST (5 mg/kg)+Iso	1.81± 0.32	0.041± 0.008
AST (10 mg/kg)+Iso	1.94± 0.25	0.052± 0.028

Data are expressed as mean±SEM (n=6). AST: Astragaloside IV. #p<0.05 from control group; *p<0.05, as compared to isoproterenol group. One way ANOVA with Tukey post- test is used.

Superoxide dismutase (SOD) and glutathione peroxide (GPx) were measured as antioxidant biomarkers. Compared to control group SOD level was lower in isoproterenol treated rat hearts (p<0.05) and administration of 2.5 mg/kg AST increased SOD level slightly (Figure 6).

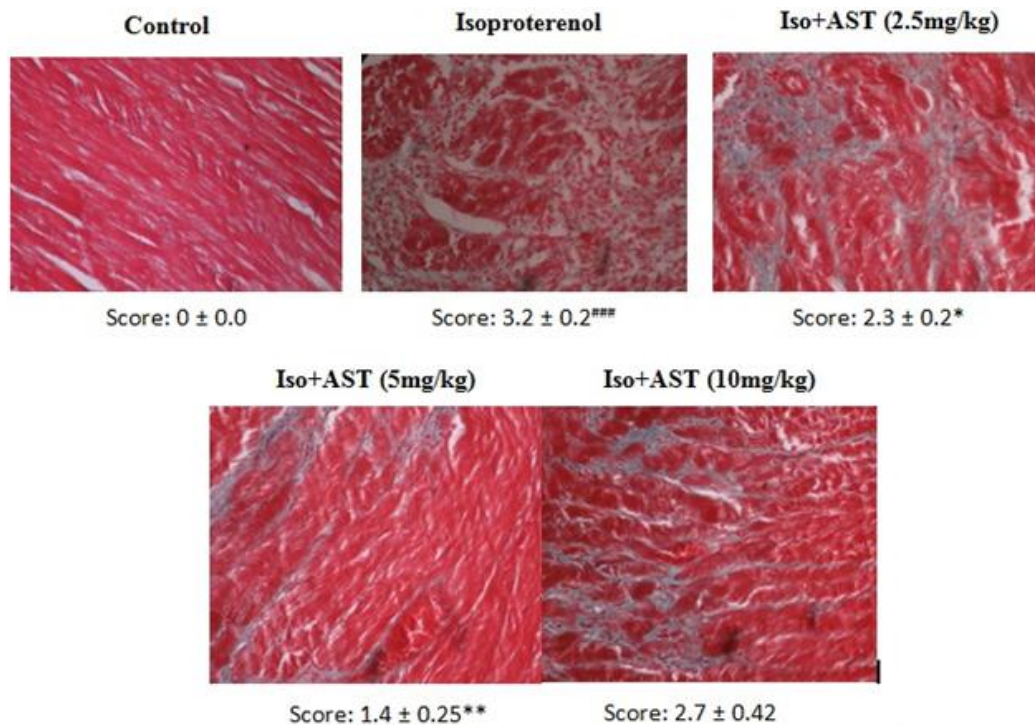


Figure 5. photomicrographs of sections of the apex of rat heart stained with Gomori Trichrome. Iso: isoproterenol; AST: Astragaloside IV. H&E (40 M). Grades of 0,1,2,3 and 4 respectively show none, low, moderate, high and intensive pathologic changes. Values are expressed as mean \pm SEM (n=6). ***p<0.001 from control group; *p<0.05 and **p<0.01 as compared to isoproterenol group. One way ANOVA with Tukey test is used.

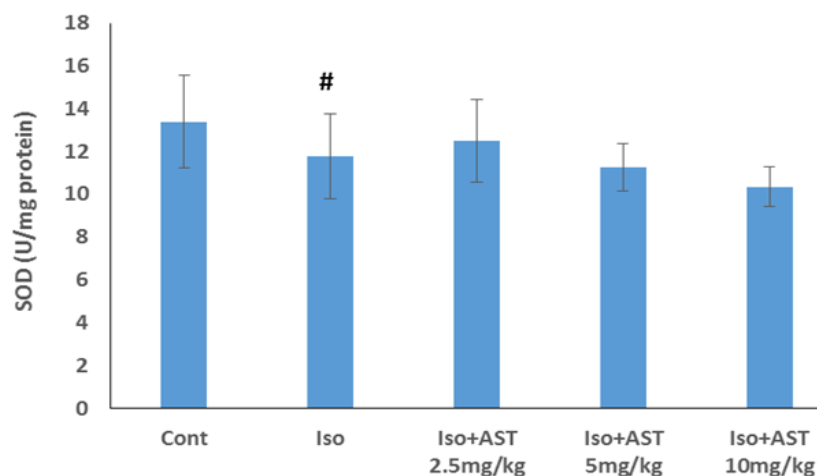


Figure 6. The effects of Astragaloside IV on superoxide dismutase (SOD) level in myocardium. Cont: Control; Iso: Isoproterenol; AST: Astragaloside IV. Values are expressed as mean \pm SEM (n=6). One way ANOVA with Tukey test is used.

Also after injection of isoproterenol, GPx level evidently decreased from 0.2 ± 0.01 u/mg protein in control group to 0.17 ($P<0.05$), and treatment with 5mg/kg AST elevated GPx level in myocardium to 0.18 ± 0.01 u/mg protein (Figure 7).

Lactic acid as a marker for myocardial ischemia was measured in serum. As it is indicated in Figure 8 isoproterenol injection produced a substantial elevation ($p<0.001$) in lactic acid level from 17.3 ± 2.4 in control group to 25.5 ± 4.2 mg/dl, whereas oral administration of all doses of AST specially 2.5 mg/kg lowered serum lactate level remarkably ($P<0.05$).

The in-vitro studies results

Effects of Astragaloside IV on flow rate changes of isolated rat heart

Figure 9 represents the change of flow rate (% of initial value) during whole period of experiment. As it is expected the flow rate had a decreasing trend over the experiment time. The administration of AST showed the same downward order with dose dependant steeper slope. In the time of 60 of experiment, the decrease in flow rate by 2 μ M AST was significant in comparison to control group.

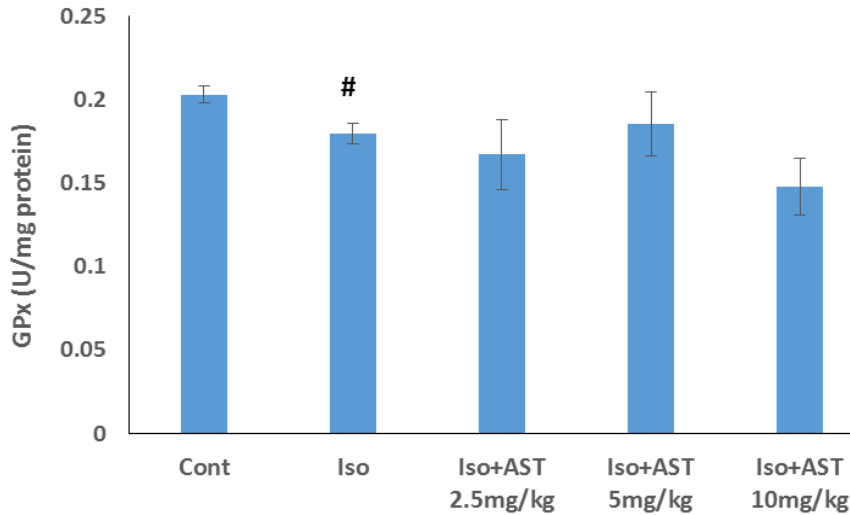


Figure 7. The effects of Astragaloside IV on glutathione peroxidase (GPx) level in myocardium. Cont: Control; Iso: isoproterenol; AST: Astragaloside IV. Values are expressed as mean±SEM (n=6). [#]p<0.05 from control group. One way ANOVA with Tukey test is used.

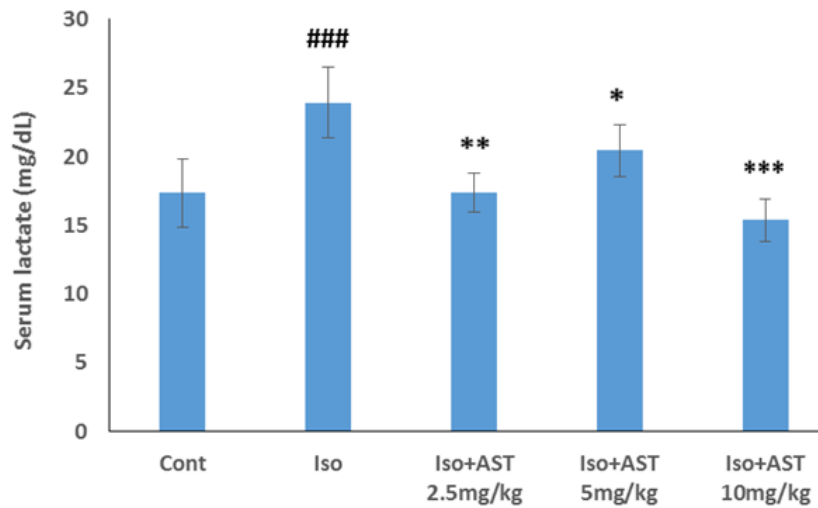


Figure 8. The effects of Astragaloside IV on serum lactic acid level. Iso: isoproterenol; ast: Astragaloside IV. Values are expressed as mean±SEM (n=6). ^{###}p<0.001 from control group; ^{*}p<0.05, ^{**}p<0.01 ^{***}p<0.001 as compared to isoproterenol group. One way ANOVA with Tukey test is used.

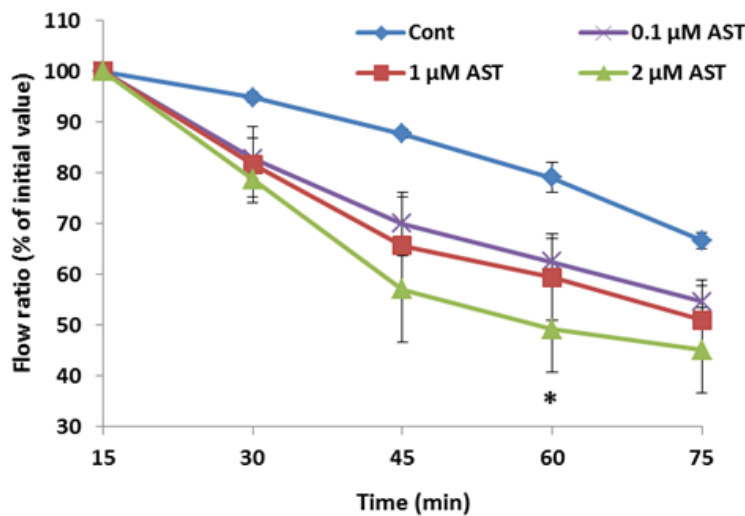


Figure 9. Perfusion rate in the control and treated groups receiving 0.1, 1 and 2 μM of Astragaloside IV during whole experiment period. Data are represented as mean±SEM. Cont: control, AST: Astragaloside IV. ^{*}p<0.05 significant difference of 0.1 μM AST from control. N=5 rats in each group.

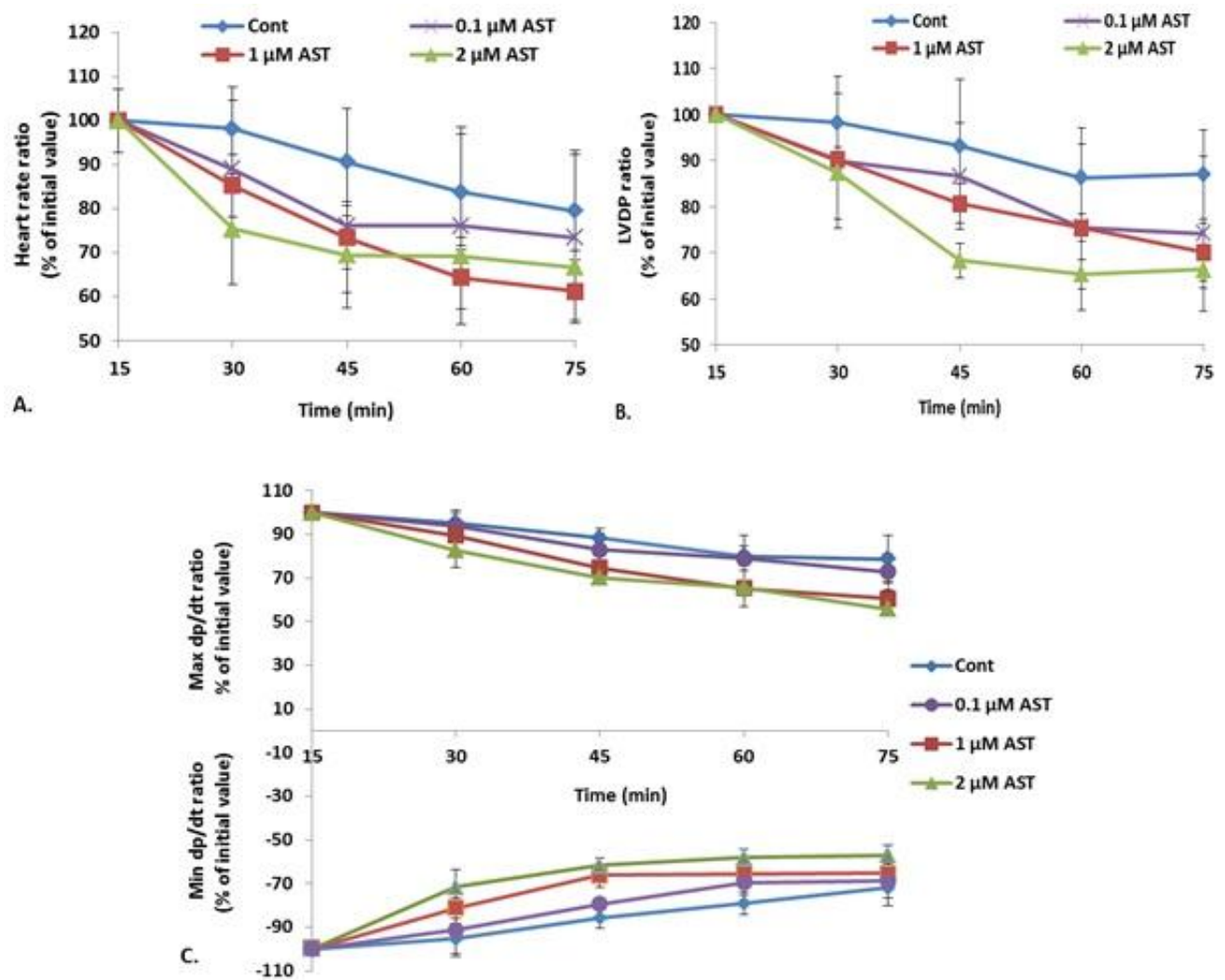


Figure 10. Hemodynamic changes in the control and treated groups receiving 0.1, 1 and 2 μM of Astragaloside IV during whole experiment period. A: Heart rate figure, B: LVDP (Left Ventricular Developed Pressure) figure, C: max and min dP/dt figure. Data are represented as mean±SEM. Cont: control, AST: Astragaloside IV. * $p < 0.05$ significant difference of 0.1 μM AST from control. N=5 rats in each group.

Effects of Astragaloside IV on hemodynamic changes of isolated rat heart

Figure 10 represents the change of hemodynamic parameters (% of initial value) during whole period of experiment. As it is demonstrated in all groups, the parameters of HR, LVDP and max and min dP/dt had a declining trend over the experiment time. However there was no significant difference in AST receiving groups compared to control group.

Discussion

In present study, we investigated the protective effects of Astragaloside IV on rats with acute myocardial infarction caused by isoproterenol injection and in isolated rat hearts. The results showed that AST can protect heart against the damage initiated by myocardial infarction evident by improvement of hemodynamic disorders, left ventricular dysfunction, heart tissue restoration, and ischemic injuries reduction associated with the decline in pre-inflammatory responses.

Subcutaneous injection of isoproterenol as a beta-

adrenergic receptor agonist immediately increases the blood pressure, but after a while it can lower arterial pressure followed by elevation in oxygen demand, hypoxia and myocardial ischemia. Resulting necrosis and cardiovascular damage; mean arterial blood pressure, heart rate and cardiac contractility are diminished.

The decrease in systolic blood pressure, diastolic blood pressure, mean arterial blood pressure, and heart rate induced by isoproterenol injection for two consecutive days, indicates a heart failure associated with myocardial infarction, which is clinically dangerous. Decrease in blood pressure and heart rate grows the requirement for oxygen. As a result, the balance between coronary blood supply and myocardial demand deteriorates and eventually leads to hypoxia and ischemic heart disease.¹⁵ Following oral administration of AST, the indicated deterioration of arterial blood pressure and heart rate was approximately improved. AST is a saponin with a steroid-like structure. For this respect, the obtained results could be due to the direct effect of AST on the heart and its quasi-steroidal structure.¹⁶ In the present study, different

doses of AST improved cardiac contractility as well. Enhancement of LVdP/dt max and LVdP/dt min, which respectively represent left ventricular contraction and relaxation markers, indicates positive inotropic effects of AST that as like as digital compounds could be attributed to the steroid-like structure of this compound. To evaluate this hypothesis, we also assessed the effects of AST in isolated rat hearts hemodynamic factors. The results of in-vitro studies demonstrated no significant difference in hemodynamic parameters, which may suggest that the positive results of hemodynamic parameters were obtained in in-vivo studies are more related to other protective role of AST such as anti-oxidant and changes in inflammatory markers of systemic circulation.

The peripheral neutrophil count is an indication of the onset of inflammatory responses following myocardial infarction, which is performed by assessing the neutrophil dispersion into the blood. Following isoproterenol injection, there is a significant augmentation in the number of neutrophils in the blood. Neutrophils have cytotoxic effects and produce inflammatory responses leading tissue degradation and production of free radicals.¹⁷ AST, especially concentrations of 5 and 10 mg/kg, significantly decreased the peripheral neutrophil count, which indicates the role of AST in preventing inflammatory responses.

The heart weight to body weight ratio is an adequate parameter to evaluate the degree of cardiac enlargement and post-MI edematous. The significant increase in this ratio after isoproterenol injection, indicate cardiac hypertrophy as a result of increased cardiac output.¹⁸ Heart weight elevation can be in regard to the increase in water volume, intramuscular edema, imbalance of protein content and cellular infiltration.¹⁹ Treatment with different doses of AST significantly reduced the heart weight to body weight ratio and inhibited cardiac hypertrophy and edematous that may be related to the anti-inflammatory effects of AST besides to improvement of hemodynamic activity.²⁰ Isoproterenol induces cardio toxicity through inducing myocardial necrosis associated with edema, tissue damage and leukocyte infiltration. Various mechanisms have been proposed to validate cardiac toxicity induced by isoproterenol such as: Hypoxia-ischemia, coronary deficiency, metabolic changes, and oxidative stress.²¹ Hypoxia-ischemia appears to be a major mechanism for toxic effects of isoproterenol. Histological examination of the heart tissue in rats receiving 100 mg/kg of isoproterenol evidently reveals signs of necrosis and hyperplasia affiliated with the intramuscular edema in H&E staining. Myocardial fibrosis is also detectable with the significant increase in fibrotic tissue marked as the blue dyed parts in Gomori Trichrome staining. Results shows that treatment with AST protects the heart against necrosis and fibrosis considerably and lessens myocardial damage and edematous caused by isoproterenol.

Active oxygen species are a major element in left ventricular disorders and myocardial infarction. One of the biochemical mechanisms of isoproterenol-induced

myocardial infarction is production of free radicals and oxidative stress. Malondialdehyde which is obtained from the oxidative decomposition of unsaturated fatty acids is an important biomarker for determination of oxidative stress and the activity of free radicals.²² Although the injection of isoproterenol increases the level of malondialdehyde, which indicates an increase in lipid peroxidation; however, different doses of AST did not show a clear effect on serum and myocardial MDA levels. Some related studies have focused on the antioxidant effects of the AST.^{23,24} but it seems that AST protects the heart against myocardial infarction primarily with different mechanisms other than lipid peroxidation pathway.

Some of the body's natural antioxidants neutralize the active oxygen species produced by isoproterenol injection. Superoxide dismutase is one of these antioxidants that catalyzes the free radicals of superoxide to oxygen and hydrogen peroxide, and by preventing oxidative activity of nitric oxide and formation of peroxynitrite radicals, inhibits cellular damage.²⁵ Glutathione peroxide, as a peroxidase, protects cells against oxidative stress by reduction of lipid hydro peroxidation to related alcohols, and converting hydrogen peroxide radicals to water.²⁶ Despite the results of previous studies that emphasize the positive effect of AST on SOD elevation and antioxidant effects of AST,²⁷ these effects were not observed in the conditions provided by this study.

Lactate levels in the clinical therapy are used as a symptom to assess the severity of the disease and evaluate the response to treatment. Ischemia caused by myocardial infarction due to decreased blood flow, as well as inflammation caused by ischemic reperfusion injury, elevates serum lactate levels.²⁸ Subcutaneous injection of isoproterenol for two constant days causes hypoxia and ischemia followed by an increase in the level of lactic acid. Meanwhile different doses of Astragaloside IV especially the dose of 2.5 mg/kg inhibited this elevation. It seems that decrease in lactic acid level is correlated with anti-inflammatory effects.

Conclusion

Present study demonstrates the protective effects of AST against isoproterenol-induced myocardial infarction in rats mainly due to its inhibitory effects on oxidative stress process. AST improved cardiac contractility and hemodynamic parameters, reduced pre-inflammatory responses as well as ischemic injuries, and helped to maintain the structure of the cardiac cells and myocardial membrane by diminishing of necrosis, edema and fibrosis of myocardial connective tissue. As the non-significant effects on hemodynamic parameters of isolated heart, the protective role of AST may be more relevant to anti-oxidative stress impacts. Eventually, with more profound studies, Astragaloside IV can be considered as a potential agent on the treatment of myocardial infarction and post-MI injuries.

Acknowledgments

The present study was supported by a grant from the Research Vice Chancellors of Tabriz University of Medical Sciences, Tabriz, Iran.

Conflict of interests

Prof. Alireza Garjani is the Editor-in-Chief of Pharmaceutical Sciences. The peer-review process of the submission was supervised by another member of the editorial board. The authors claim no other competing interests.

References

- Farvin KH, Anandan R, Kumar SH, Shiny KS, Mathew S, Sankar TV, et al. Cardioprotective effect of squalene on lipid profile in isoprenaline-induced myocardial infarction in rats. *J Med Food*. 2006;9(4):531-6. doi:10.1089/jmf.2006.9.531
- Grimm D, Elsner D, Schunkert H, Pfeifer M, Griese D, Bruckschlegel G, et al. Development of heart failure following isoproterenol administration in the rat: Role of the renin-angiotensin system. *Cardiovasc Res*. 1998;37(1):91-100. doi:10.1016/s0008-6363(97)00212-5
- Welbourn CR, Goldman G, Paterson IS, Valeri CR, Shepro D, Hechtman HB. Pathophysiology of ischaemia reperfusion injury: Central role of the neutrophil. *Br J Surg*. 1991;78(6):651-5. doi:10.1002/bjs.1800780607
- Cragg GM, Newman DJ. Natural products: A continuing source of novel drug leads. *Biochim Biophys Acta Gen Subj*. 2013;1830(6):3670-95. doi:10.1016/j.bbagen.2013.02.008
- Pinn G. Herbs and cardiovascular disease. From past to present. *Aust Fam Physician*. 2000;29(12):1149-53.
- Bachschnid MM, Schildknecht S, Matsui R, Zee R, Haeussler D, Cohen RA, et al. Vascular aging: Chronic oxidative stress and impairment of redox signaling-consequences for vascular homeostasis and disease. *Ann Med*. 2013;45(1):17-36. doi:10.3109/07853890.2011.645498
- Tang W, Eisenbrand G. Chinese drugs of plant origin: Chemistry, pharmacology, and use in traditional and modern medicine. Berlin: Springer-Verlag; 1992.
- Zhang WD, Chen H, Zhang C, Liu RH, Li HL, Chen HZ. Astragaloside iv from *Astragalus membranaceus* shows cardioprotection during myocardial ischemia in vivo and in vitro. *Planta Med*. 2006;72(1):4-8. doi:10.1055/s-2005-873126
- Zhao Z, Wang W, Wang F, Zhao K, Han Y, Xu W, et al. Effects of astragaloside iv on heart failure in rats. *Chin Med*. 2009;4(1):6. doi:10.1186/1749-8546-4-6
- Tang B, Zhang JG, Tan HY, Wei XQ. Astragaloside iv inhibits ventricular remodeling and improves fatty acid utilization in rats with chronic heart failure. *Biosci Rep*. 2018;38(3):BSR20171036. doi:10.1042/bSR20171036
- Yang J, Wang HX, Zhang YJ, Yang YH, Lu ML, Zhang J, et al. Astragaloside iv attenuates inflammatory cytokines by inhibiting tlr4/nf-small ka, cyrillicb signaling pathway in isoproterenol-induced myocardial hypertrophy. *J Ethnopharmacol*. 2013;150(3):1062-70. doi:10.1016/j.jep.2013.10.017
- Fathiazad F, Khosropanah MK, Movafeghi A. Cycloartane-type glycosides from the roots of *Astragalus caspicus* bieb. *Nat Prod Res*. 2010;24(11):1069-78. doi:10.1080/14786410902975582
- Satoh K. Serum lipid peroxide in cerebrovascular disorders determined by a new colorimetric method. *Clin Chim Acta*. 1978;90(1):37-43. doi:10.1016/0009-8981(78)90081-5
- Garjani A, Vaez H, Delazar A, Rameshrad M, Heshmati Afshar F, Asgharian P. Cardioprotective effects of methanolic extract of *Scrophularia frigidula* on ischemia-reperfusion-induced injuries in isolated rat heart. *Iran J Pharm Res*. 2017;16(Suppl):35-45.
- Yeager JC, Iams SG. The hemodynamics of isoproterenol-induced cardiac failure in the rat. *Circ Shock*. 1981;8(2):151-63.
- Kim YB, Thwe AA, Li X, Tuan PA, Lee S, Lee JW, et al. Accumulation of astragalosides and related gene expression in different organs of *Astragalus membranaceus* bge. Var mongholicus (bge.). *Molecules*. 2014;19(8):10922-35. doi:10.3390/molecules190810922
- Kela AK, Reddy LP, Thombre DP. E.C.G. Findings in normal rats and after administration of isoproterenol. *Indian J Physiol Pharmacol*. 1980;24(2):84-90.
- Ozaki M, Kawashima S, Yamashita T, Hirase T, Ohashi Y, Inoue N, et al. Overexpression of endothelial nitric oxide synthase attenuates cardiac hypertrophy induced by chronic isoproterenol infusion. *Circ J*. 2002;66(9):851-6. doi:10.1253/circ.j.66.851
- Patel V, Upaganlawar A, Zalawadia R, Balaraman R. Cardioprotective effect of melatonin against isoproterenol induced myocardial infarction in rats: A biochemical, electrocardiographic and histoarchitectural evaluation. *Eur J Pharmacol*. 2010;644(1-3):160-8. doi:10.1016/j.ejphar.2010.06.065
- Lee DY, Noh HJ, Choi J, Lee KH, Lee MH, Lee JH, et al. Anti-inflammatory cycloartane-type saponins of *Astragalus membranaceus*. *Molecules*. 2013;18(4):3725-32. doi:10.3390/molecules18043725
- Chagoya de Sanchez V, Hernandez-Munoz R, Lopez-Barrera F, Yanez L, Vidrio S, Suarez J, et al. Sequential changes of energy metabolism and mitochondrial function in myocardial infarction induced by isoproterenol in rats: A long-term and integrative study. *Can J Physiol Pharmacol*. 1997;75(12):1300-11. doi:10.1139/y97-154
- Grune T, Berger MM. Markers of oxidative stress in ICU clinical settings: Present and future. *Curr Opin Clin Nutr Metab Care*. 2007;10(6):712-7. doi:10.1097/MCO.0b013e3282f0c97c

23. Luo Y, Qin Z, Hong Z, Zhang X, Ding D, Fu JH, et al. Astragaloside iv protects against ischemic brain injury in a murine model of transient focal ischemia. *Neurosci Lett*. 2004;363(3):218-23. doi:10.1016/j.neulet.2004.03.036
24. Qiu LH, Xie XJ, Zhang BQ. Astragaloside IV improves homocysteine-induced acute phase endothelial dysfunction via antioxidation. *Biol Pharm Bull*. 2010;33(4):641-6. doi:10.1248/bpb.33.641
25. Fukui T, Ushio-Fukai M. Superoxide dismutases: Role in redox signaling, vascular function, and diseases. *Antioxid Redox Signal*. 2011;15(6):1583-606. doi:10.1089/ars.2011.3999
26. Lubos E, Loscalzo J, Handy DE. Glutathione peroxidase-1 in health and disease: From molecular mechanisms to therapeutic opportunities. *Antioxid Redox Signal*. 2011;15(7):1957-97. doi:10.1089/ars.2010.3586
27. Ma Z, Yang Z. scavenging effects of *Astragalus* and *Gynostemma pentaphyllum* with its product on o2-. *And .Oh. Zhong Yao Cai*. 1999;22(6):303-6.
28. Andersen LW, Mackenhauer J, Roberts JC, Berg KM, Cocchi MN, Donnino MW. Etiology and therapeutic approach to elevated lactate levels. *Mayo Clin Proc*. 2013;88(10):1127-40. doi:10.1016/j.mayocp.2013.06.012