



Heterotopic Gastric Mucosa in the Gallbladder Simulating a Tumor: A Case Report

**Taoufik Elabbassi^{1*}, Yassine Fakhri¹, Abdessamad Elazhary¹
and M. Rachid Lefriyekh¹**

¹*Faculty of Medicine and Pharmacy of Casablanca, General Surgery Service I, Ibn Rochd University
Hospital Center, Hassan II University, Casablanca, Morocco.*

Authors' contributions

This work was carried out in collaboration among all authors. All authors read and approved the final manuscript.

Article Information

DOI: 10.9734/JAMMR/2019/v31i1130279

Editor(s):

(1) Prof. Dr. Emin Umit Bagriacik, Director, Immunology Research Center, Gazi University, Faculty of Medicine, Department of Immunology, Besevler, 06560 Ankara-Turkey.

Reviewers:

(1) Rahul Gupta, Synergy Institute of Medical Sciences, India.
(2) Ashrarur Rahman Mitul, Dr. MR Khan Shishu Hospital and Institute of Child Health, Bangladesh.
Complete Peer review History: <https://sdiarticle4.com/review-history/52410>

Case Report

Received 02 September 2019

Accepted 05 November 2019

Published 19 November 2019

ABSTRACT

Heterotopia is defined as an ectopic localization of normal tissue; the heterotopia of the gastric mucosa can be observed all along the digestive tract. The localization in the gallbladder is exceptional. The diagnosis is histological, it may present some complications including ulceration and the risk of malignancy.
We report the case of heterotopia of the gastric mucosa in the gallbladder while presenting the clinical, radiological and therapeutic features of this exceptional lesion.

Keywords: Heterotopic gastric mucosa; gallbladder; surgery; histology.

1. INTRODUCTION

Heterotopic or ectopic tissue is a congenital anomaly, which is defined as the presence of the

tissue outside its normal location, without neural, vascular, or anatomic connection with the main body of an organ in which it normally exists. Pancreatic and gastric heterotopias are the two

*Corresponding author: E-mail: elabbassi.taoufik@gmail.com;

predominantly occurring heterotopic tissues in the gastrointestinal tract [1].

Heterotopic gastric tissue can be found in the entire gastrointestinal tract. Rarely, it can be found in the gallbladder [2].

2. CASE REPORT

We report the case of a 68-year-old female patient, with history of hypertension treated with Amlodipine and dyslipidemia with simvastatin, who for the last 1 year has had right hypochondrial pain radiating to the right shoulder, without clinical cholestasis syndrome or other associated signs, the whole evolving in a context of apyrexia and conservation of the general state.

The clinical examination found sensitivity in the right hypochondrium. The abdominal ultrasound

had showed a gallbladder full of a sludge, with the presence of a hyperechogenic mass, homogeneous with irregular limits at its fundus. The laboratory data showed elevated Gama GT level at 276UI / L. A biliary MRI revealed at the fundus of the gallbladder, a biliary lesion process, connecting to the anterior wall in intermediate signal T1, hypersignal T2, enhancing heterogeneously after Gadolinium injection, measuring 21x21x13mm, integrity of vesicular wall, liver and pervesicular fat related to an endo vesicular tumor process, without dissemination to the liver parenchyma.

Abdominal computed tomography (CT) showed a distended gallbladder with an endoluminal budding formation, irregular contours apiece to the thickened fundus wall, measuring 20.5x19.5x10.5mm, The absence of bile duct dilatation. Image of a tumoral process of the gallbladder.

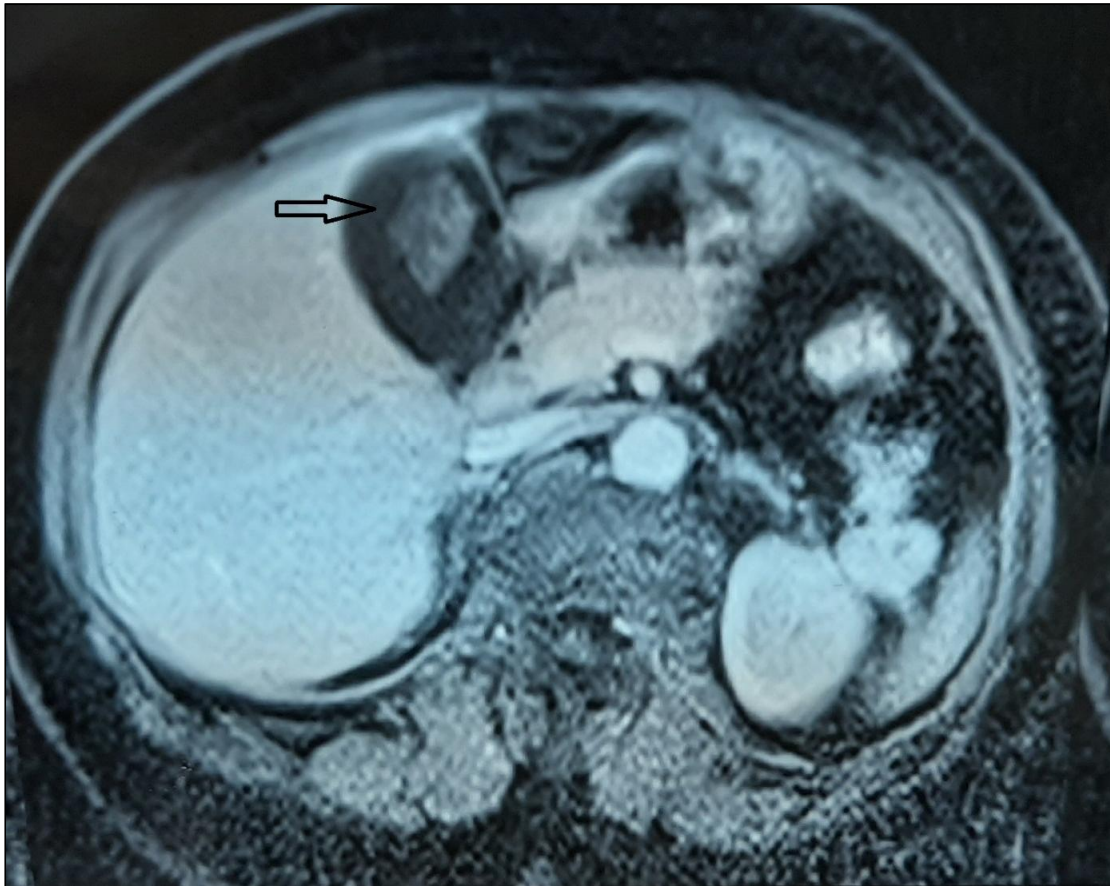


Fig. 1. Biliary magnetic resonance imaging (MRI) in axial section: budding lesion process at the fundus of the gallbladder

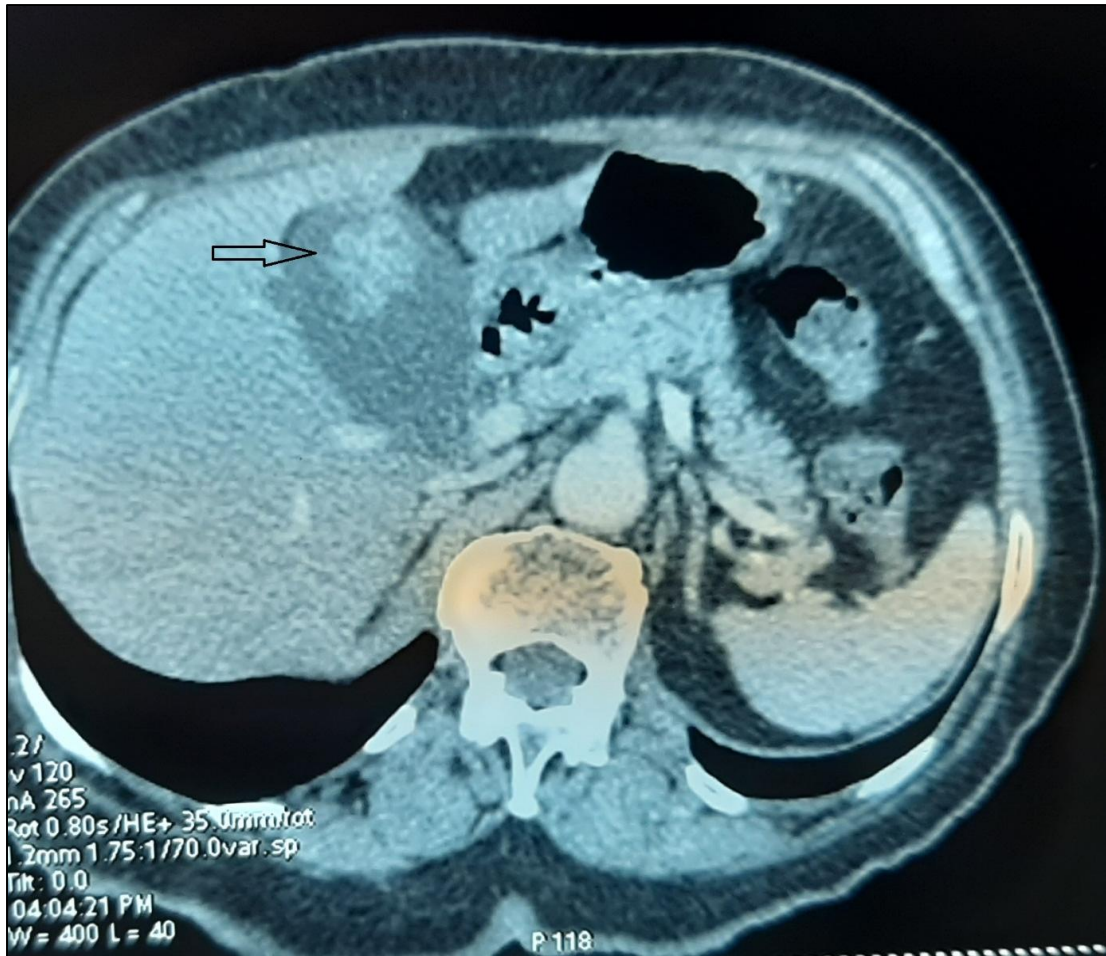


Fig. 2. Abdominal computed tomography in axial section showing at the fundus of the gallbladder an endoluminal formation

The tumor markers carbohydrate antigenic determinant 19-9 (CA 19-9) and carcinoembryonic antigen (CEA) were normal.

The intervention consisted of a cholecystectomy with right costal laparotomy, the anatomopathological study of the part, which had Macroscopically shown that The wall of the gallbladder's fundus is occupied by a polypoid formation at 5 cm from its neck, this wall looks as well thick. Microscopically, the polypoid formation described above is a vesicular mucosa raised by a gastric mucosa of pyloric type gland, bordered by regular cells, with basal nucleus, and with fine chromatin, without mitosis analyzable, the axis polyp is fibro-vascular.

The vesicular coating elsewhere is regular, without signs of dysplasia, with lesions of chronic cholecystitis.

3. DISCUSSION

Heterotopia, from the Greek "heteros" (different) and topos ("location" or "localization") is defined as the occurrence of normal tissue in abnormal location, the heterotopia of the gastric mucosa can be observed all along the digestive tract [3], from the tongue [4], to the rectum and the anus [5]. The localization in the gallbladder is exceptional. The first case of HGM in the gallbladder was reported in Hungary in 1934 [6]. In Japan, 19 cases have been reported to the present, since the first case reported by Tomita in 1977 [7]; 45 cases in Europe by Xeropotamos and Vallera [4,8].

Two pathophysiological hypotheses have been put forward to explain the heterotopia of the gastric mucosa: Metaplasia and ectopic differentiation. Ectopic differentiation is of

embryonic origin and may involve the epithelium of the digestive tract as well as hepatic and pancreatic parenchyma; all structures emanating from the primitive intestine. Given the common origin of these tissues developed from the primitive intestine, which is lined with pluripotent cells capable of differentiating into several lineages, it is likely that heterotopia of the gastric mucosa results from a congenital ectopic localization of the tissue and that pluripotent cells differentiate from an abnormal location.

Metaplasia is defined as an acquired change from one tissue to another; it is usually induced by chronic inflammation [9].

Previously, a male predominance was described in the literature [10].

Gastric heterotopia in the gall bladder may be asymptomatic or in the form of pain in the right hypochondrium radiating to the right shoulder, as in our patient's case [11].

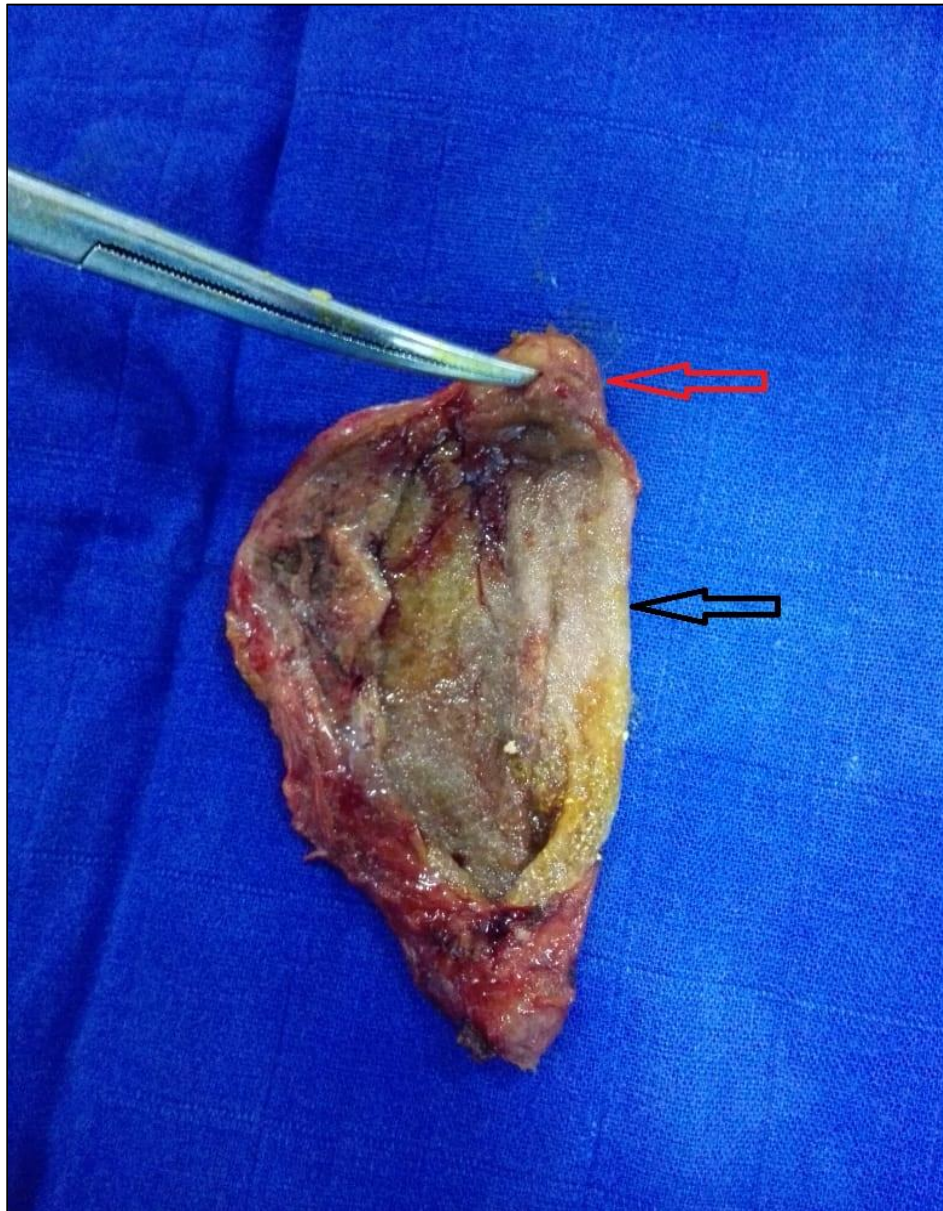


Fig. 3. The gallbladder with gastric mucosa (red arrow) and mucous membrane of the gallbladder (black arrow)

Previously, findings regarding serological parameters have been rarely described in the literature [12].

Imaging modalities are of special importance in gallbladder diagnostics. The most common and most accessible modality is ultrasound. In ultrasound, heterotopic gastric mucosa depicts itself as a polypoid mass either broad based or sessile [13]. Another form can be shown as a focal wall thickening. Sometimes, it can present as a cystic lesion in the event of secreting gastric mucus without a possibility of draining. The solid mass is usually hyperechoic, less commonly isoechoic, ranging in size from 0.5 to 3 cm.

Regarding CT-findings, lesions were slightly hyperdens. There is paucity of MRI data regarding heterotopic gastric mucosa [14].

Histopathological diagnosis of gastric heterotopia is based on the presence of fundic or pyloric mucosa replete with parietal and chief cells. The heterotopic gastric tissue is mostly situated in the neck of the gallbladder or cystic duct [7].

Some potentially important complications must also be considered when we deal with heterotopic gastric mucosa in the gallbladder, including ulceration of the gallbladder and possible malignant changes. Although a few cases of mucosal ulceration have been reported in the English-language literature [15], no cases of mucosal ulceration have been reported in Japan. This low frequency of mucosal ulceration has been attributed to the ability of the alkaline contents of the bile to neutralize acidic contents. Many Authors suggested that heterotopic gastric mucosa may have the potential for carcinogenesis, as a polyp, but so far no cases of malignant changes have been reported [16].

Heterotopia of the gastric mucosa is a differential diagnosis of polyps of the gall bladder, especially in the elderly. A cholecystectomy must be performed in principle in front of any symptomatic polyp of the gallbladder regardless of its size and in case of asymptomatic polyp with a diameter greater than or equal to one centimeter [9].

4. CONCLUSION

Heterotopia of the gastric mucosa in the gallbladder is a rare pathology, may be asymptomatic or in the form of hepatic colic, the diagnosis is histological.

The surgeon must think of this differential diagnosis in the presence of any vesicular polyp.

This exceptional lesion can lead to certain complications, including ulceration and the risk of cancer.

CONSENT

As per international standard or university standard, patient's consent has been collected and preserved by the authors.

ETHICAL APPROVAL

As per international standard, ethical approval has been collected and preserved by the author.

COMPETING INTERESTS

Authors have declared that no competing interests exist.

REFERENCES

1. Pendharkar D, Khetrapal S, Jairajpuri ZS, Rana S, Jetley S. Pancreatic and Gastric Heterotopia in the Gallbladder: A Rare Incidental Finding. *Int J Appl Basic Med Res.* 2019;9(2):115–117.
2. Cöl C, Boran C, Turkeli V, Dinler K, Kordon O, Erkol H, et al. Heterotopic gastric mucosa in gallbladder associated with kidney agenesis and congenital hip dysplasia. *Acta Clin Belg.* 2007;62(2):120–122.
3. Satoh S, Nakashima T, Watanabe K, Toda S, Kuratomi Y, Sugihara H, et al. Hypopharyngeal squamous cell carcinoma bordering ectopic gastric mucosa "inlet patch" of the cervical esophagus. *Auris Nasus Larynx.* 2007;34(1):135–139.
4. Xeropotamos N, Skopelitou AS, Batsis C, Kappas AM. Heterotopic gastric mucosa together with intestinal metaplasia and moderate dysplasia in the gall bladder: report of two clinically unusual cases with literature review. *Gut.* 2001;48(5):719–723.
5. Asiani S, Vilmann P, Pilt AP. Ectopic gastric mucosa in the rectum. *Ugeskr Laeger.* 2005;167(16):1757-1759.
6. Egyedi L. Case of polypus of gallbladder containing aberrant gastric mucous membrane (in Hungarian). *Gyogyaszat (Gyogyastat).* 1934;74:596-599.

7. Hamazaki K, Fujiwara T. Heterotopic gastric mucosa in the gallbladder. *J Gastroenterol.* 2000;35(5):376–381.
8. Vallera D, Dawson P, Path F. Gastric heterotopia in the gallbladder. Case report and review of literature. *Pathol Res Pract.* 1992;188(1-2):49-52.
9. Triki E, Brigand C, Meyer C. Hétérotopie de muqueuse gastrique dans la vésicule biliaire. *Journal de Chirurgie.* 2008;145(4): 376–377.
10. Verbo A, Manno A, Mattana C, Coco C, Sermoneta D, Vecchio FM, et al. Peptic ulcer in gastric heterotopia of the gallbladder without evidence of *Helicobacter pylori* infection. *Dig Dis Sci.* 2007;52(9):2201–2203.
11. Hayama S, Suzuki Y, Takahashi M, Hazama K, Fujita M, Kondo S, et al. Heterotopic gastric mucosa in the gallbladder: report of two cases. *Surg Today.* 2010;40(8):783–787.
12. Wlaż J, Mądro A, Kaźmierak W, Celiński K, Słomka M. Pancreatic and gastric heterotopy in the gastrointestinal tract. *Postepy Hig Med Dosw (Online).* 2014; 68:1069–1075.
13. Sciumè C, Geraci G, Pisello F, Li Volsi Facella FT, Modica G. Heterotopic gastric mucosa in the gallbladder: case report and literature review, *Ann. Ital. Chir., LXXVI,* 2005;193-97.
14. Beeskow AB, Meyer H-J, Schierle K, Surov A. Heterotopic gastric mucosa in gallbladder—A rare differential diagnosis to gallbladder masses: A systematic review. *Medicine.* 2018;97(10): e0058.
15. Adam R, Fabiani B, Bismuth H. Hematobilia resulting from heterotopic stomach in the gallbladder neck. *Surgery.* 1989;105(4):564–569.
16. Ishii Y, Ohmori K, Suzuki M, Hoshi T, Watanabe I, Endo S. [Heterotopic gastric mucosa in the wall of the gallbladder: a case report and review of the literature]. *Nihon Geka Gakkai Zasshi.* 1985;86:868-876.

© 2019 Elabbassi et al.; This is an Open Access article distributed under the terms of the Creative Commons Attribution License (<http://creativecommons.org/licenses/by/4.0>), which permits unrestricted use, distribution, and reproduction in any medium, provided the original work is properly cited.

Peer-review history:
The peer review history for this paper can be accessed here:
<https://sdiarticle4.com/review-history/52410>