



Two Cases Diagnosed with Idiopathic Root Resorption and Low Serum Vitamin D Raise New Questions on Aetiology

**Inger Kjaer^{1*}, Georges Rozenzweig², Eric Foultier³, Maria Lopez Petersen⁴,
Niels Tommerup⁵, Mads Bak⁶ and Jan Květný⁷**

¹*Department of Odontology, Faculty of Health Sciences, University of Copenhagen Nørre Alle 20, 2200 Copenhagen N, Denmark.*

²*Private Practice Grenoble, France.*

³*Private Practice Coulevie, France.*

⁴*Community Dental Service, Haderslev, Denmark.*

⁵*Department of Cellular and Molecular Medicine, Faculty of Health Sciences, University of Copenhagen, Copenhagen, Denmark.*

⁶*Department of Clinical Genetics 4062, Copenhagen University Hospital, Copenhagen, Denmark.*

⁷*Department of Endocrinology, University of Southern Denmark, Odense, Denmark.*

Authors' contributions

This work was carried out in collaboration among all authors. Author IK responsible for the hypothesis. Designed the study; contacted and cooperated with the specialists and compiled the text. Author GR responsible for anamnesis and radiographs of the permanent dentition in Patient A. Author EF responsible for the primary dentition, anamneses and radiographs in Patient A. Author MLP responsible for anamnesis and radiographs in Patient B. Author NT responsible for planning and evaluation of genetic investigations including text to this part of the study. Author MB responsible for performing and describing the genotypic investigation. Author JK Responsible for the overall endocrine insight, planning, evaluation of the serum tests and the text to this part of the study. All authors read and approved the final manuscript.

Article Information

Editor(s):

(1) Dr. Roberta Gasparro, University of Naples Federico II, Italy.

Reviewers:

(1) Maria Cristina Sifuentes Valenzuela, Universidad Nacional Autónoma de México, México.

(2) Suely Cristina Aragão Veras dos Santos, Paulo Picanço College, Brazil.

Complete Peer review History: <http://www.sdiarticle4.com/review-history/66429>

Case Study

Received 14 January 2021

Accepted 18 March 2021

Published 30 March 2021

ABSTRACT

Aims: In this report, two cases, A and B, with idiopathic resorptions are presented. In both cases the hypothesis was that the idiopathic resorption processes had a general medical cause, presumably an inborn calcification deficit. The aim was to evaluate this hypothesis.

Presentation of Cases: Case A. Healthy Caucasian male, born 1999, with no anamnestic information on diseases or medications, was treated with orthodontic fixed appliances for agenesis of a mandibular incisor, lack of space in the maxilla for cuspid eruption and bilateral open bite. A sister had minor resorption defects after orthodontic treatment. What is extraordinary in case A, and seemingly not described before, is the aggressive resorption occurring in the retention period and in the 4-year post retention period.

Case B. Caucasian male, born in a pre-term delivery in 2003 with an anamnestic information on late development and ADHD. Case B has never received orthodontic treatment. Both patients underwent a serum test and case A was also offered a genetic test.

Findings: Cases A and B both had low values of vitamin D. In addition, case B had low value of alkaline phosphatase (ALP). Case A was genetically negative for hypophosphasia (HPP).

By retrospection, both cases revealed severe resorption in the primary dentition before onset of orthodontic treatment.

Conclusion: It was concluded that the resorptions observed in the permanent teeth in case A was not a consequence of the orthodontic treatment. It is suggested that case A could have osteomalasia, while case B may have HPP.

Limitations: This study represents a new approach in revealing the aetiology behind severe idiopathic root resorption. Further collaboration with medical specialists is need for improving the indications and the limitations for the serological methods.

Keywords: Root resorption; idiopathic; vitamin D; alkaline phosphatase; bone disease; orthodontics.

1. INTRODUCTION

1.1 Aims

It is well known that short dental roots can be an inborn malformation but it is also generally accepted that short roots can be caused by external factors such as trauma and pressure from cysts and orthodontic appliance. Furthermore, resorption can occur without pressure or other external influences [1].

1.1.1 The hypothesis behind the resorption process

The hypothesis behind the resorption process could be that the process is caused by an inborn mineralization defect in the cementum/dentine or by resorbing cells in the specific tissue layers covering the root surface [2].

The specific tissue layers covering the root surface have been analysed histochemically. This investigation revealed that a peri-root sheet, composed by three distinct vascular layers covered the root [3]. These layers are an innervation layer close to the root (inner layer), a mesodermal layer (middle layer) and an epithelial layer, the Malassez epithelium (outer layer).

Except for the epithelial layer, the covering of the root resembles a periosteum covering the bone tissue.

1.1.2 Resorption after orthodontic treatment

It is important not only to predict but also to prevent resorption caused by orthodontic treatment. In different publications, focus has been on morphological signs in the permanent dentitions important for prediction and prevention of resorption before treatment onset [4].

Abnormal resorption of primary teeth in a dentition has also been mentioned in the literature as a risk factor for later resorption of permanent teeth in the same dentition. This aspect has never been associated with specific morphologies in the permanent dentition [4].

1.1.3 Idiopathic resorption

Idiopathic resorption occur without known aetiology, and accordingly not as a consequence of orthodontic treatment. If the morphological signs predicting later resorption do not exist, then later resorption can be unexpected and accordingly idiopathic. There is an extensive need for understanding the aetiology behind

idiopathic root resorption. The aim of this study was to focus on the aetiology behind this abnormal and unexpected resorption processes in two patient cases.

1.2 Presentation of Cases

1.2.1 Case A, clinical phenotype

Case A, a healthy Caucasian male, born 1999, with no anamnestic information on diseases or medications, was treated with orthodontic fixed appliances for agenesis of a mandibular incisor, lack of space in the maxilla for cuspid eruption and bilateral open bite. The patient had a 2 years older sister, who in relation to orthodontic treatment developed minor root resorptions of the incisors.

The first orthopantomogram of case A was taken at the age of 10 years (Fig. 1, upper). The orthodontic treatment with fixed appliances started at the age of 11 years and 2 months.

The treatment lasted 34 months from age 11 years and 2 months to age 14 years. At this time, the orthodontic treatment was interrupted due to observation of resorption, though unfinished. The orthopantomogram taken when the treatment was interrupted at the age of 14 years (Fig. 1, lower) demonstrated severe resorption of the maxillary first molars and maxillary incisors and of the distal roots of the mandibular first molars and two incisors as well. The trabecular or the cancellous bone in the jaws appeared lobulated and the cortical bone delicate.

After interruption of the orthodontic treatment there was a 2 years retention period ending at the age of 16 years, when another orthopantomogram was taken for control of resorption (Fig. 2, upper).

The orthopantomogram from the end of the 2 years retention period documented that the root resorption had progressed severely in the maxilla as well as in the mandible.

At the age of 20 years, a 4 years post retention radiographic control of the dentition was performed (Fig. 2, lower). The radiograph demonstrated that the resorption had further progressed in the post retention period. The post retention control demonstrated complete resorption of several maxillary molar roots and nearly complete root resorption of the second maxillary premolars. In addition, the other

maxillary teeth had shortened severely. In the mandible, nearly all mandibular roots had resorbed completely. Bone structures observed in the orthopantomogram demonstrated extremely irregular cancellous bone and in the maxillary molar region, a circular contour was observed. This contour could presumably be a recess from the expanding maxillary sinus during growth.

The orthopantomograms from case A were referred in 2019 to the first author, IK, for explanation of the aggressive resorption observed. For unravelling the aetiology, all radiographs from the primary dentitions were requested. These radiographs are demonstrated in Fig. 3. The radiographs were taken at the age of 6 years for control of permanent tooth emergence. Severe and abnormal resorption processes occurred in several primary molars.

1.2.2 Summary of case A

What is extraordinary in this case and seemingly not described before, is the aggressive resorption occurring in the retention period and in the 4 years post retention period. Normally the resorption process would have stopped after the orthodontic treatment period but in this case, the resorption of the mesenchymal-derived root dentin aggravated remarkably and in the last taken orthopantomogram several teeth appeared rootless. Also, the observation of abnormal bone contours is remarkable.

Furthermore, and for retrospection, the requested radiographs from the primary dentitions indicated a general tendency to idiopathic resorption in both dentitions.

1.2.3 Case B, clinical phenotype

Case B was from a Caucasian male, born in a pre-term delivery in 2003, with an anamnestic information on late development and ADHD. Case B never received orthodontic treatment. The first orthopantomogram from age 15 years revealed several resorption defects especially in the second maxillary molars (Fig 4, upper). These molars were extracted for creating space for the third molars. A follow up radiograph was taken at the age of 16 years and 3 months (Fig 4, lower). This orthopantomogram demonstrated that the resorption had severely progressed in the maxillary and in the mandibular teeth. Also, in this case irregular pattern in the spongy bone

and extreme thin cortical bone structure were observed.

Case B was referred to Center for Rare Craniofacial diseases at the University in Aarhus in 2014 due to root resorption in the maxillary incisors. Furthermore, the case was forwarded to the first author, IK, in 2018 for discussion of the first orthopantomogram (Fig 4, upper) and in

2020 for discussion of the follow up radiograph (Fig 4, lower). After the second orthopantomogram the available radiographs from the primary dentition were requested. Only one radiograph of the primary teeth existed (Fig 5). This radiograph demonstrated a severe and abnormal resorption defect in the maxillary second primary molar.

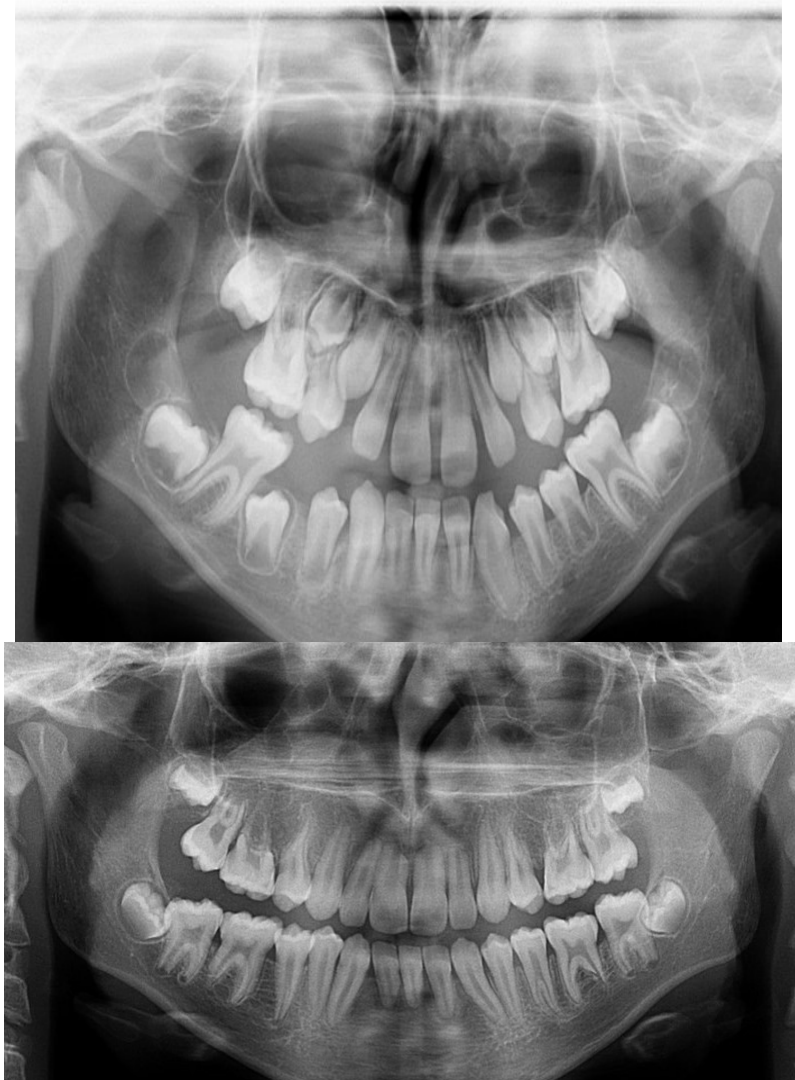


Fig. 1. Case A Upper: Orthopantomogram from the patient, 10 years of age, taken due to orthodontic treatment planning. Orthodontic appliances were inserted later. The orthopantomogram illustrates severe crowding in the maxillary canine/premolar regions and agenesis of one mandibular incisor. Lower: Orthopantomogram from the patient, 14 years of age, when treatment was interrupted due to root resorptions. The orthodontic treatment had lasted 34 months. The orthopantomogram demonstrates severe resorption in the maxillary first molars and maxillary incisors. In the mandible resorption appeared in the distal roots of the first molars and on two incisors. The cancellous bone appears lobulated and the cortical bone delicate

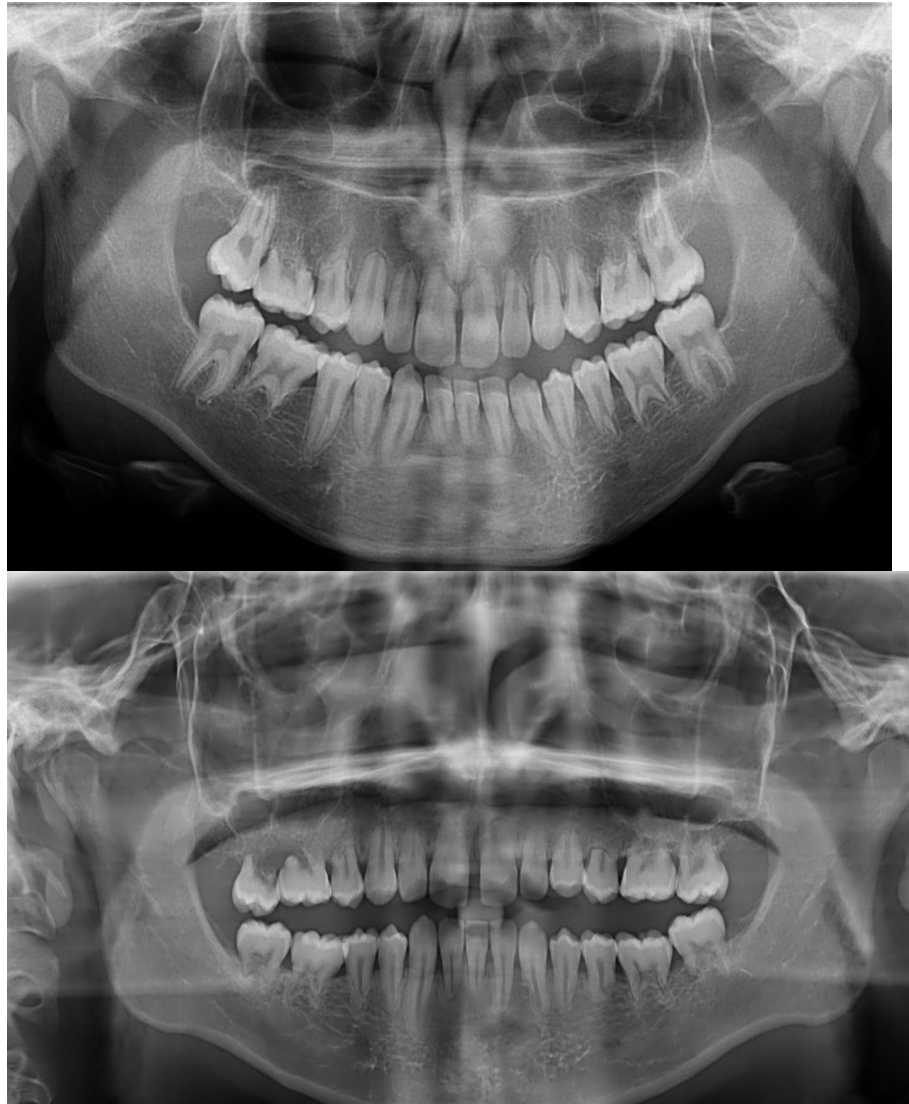


Fig. 2. Case A: Upper: Orthopantomogram from the patient, 16 years of age. The orthopantomogram was taken as control after the two years retention period ended. The root resorption has progressed severely, compared to Fig. 1 as well as in the maxilla as in the mandible. Lower: Orthopantomogram from the patient, 20 years of age. The resorption has progressed severely during the four years' post retention period. In the four years period there has been no orthodontic treatment and no retention. The orthopantomogram illustrates complete resorption of several maxillary molar roots and nearly complete root resorption of the second maxillary premolars. Also, the other maxillary teeth have shortened severely. In the mandible, nearly all mandibular roots have resorbed completely. The other teeth in the mandible are severely resorbed except the right canine. Bone structures: The cancellous network appear extremely irregular. A circular contour is observed in the region of the right sectioned maxillary molar. This contour is presumably a new recess from the maxillary sinus. These two radiographs demonstrate how severe progressive resorption of the mesenchymal originated dentin can occur within 4 years without any orthodontic treatment

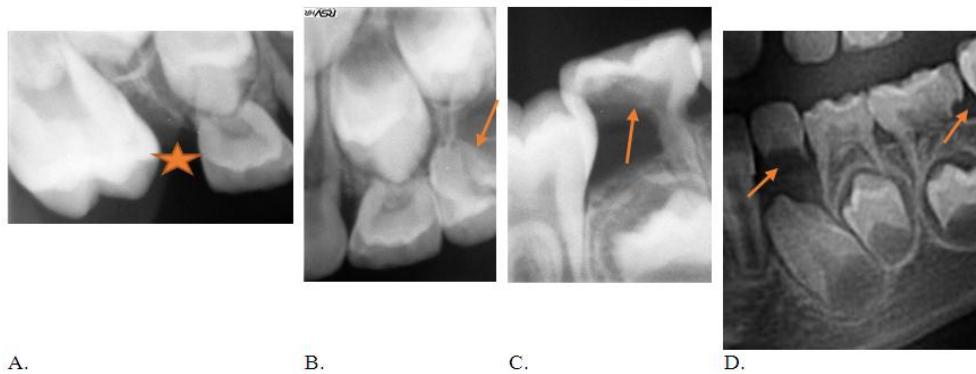


Fig. 3. Case A: Radiographs demonstrating abnormal resorption of primary teeth. A: At the age of 6 years the right maxillary secondary primary molar was completely resorbed and exfoliated due to eruption of the first permanent molar. The area marked with a star indicates the region where the second primary molar normally would have been located at the age of 6 years. B, C: Dental films from age 6 years illustrating abnormal resorption of primary second molars (marked by arrows) in the left side of the maxilla (B) and in the right side of the mandible (C) due to pressure from erupting first molars. D: Section from an orthopantomogram from age 7 years illustrating abnormal resorption of the mandibular left primary canine and the mandibular left primary second molar. The resorption areas are marked by arrows

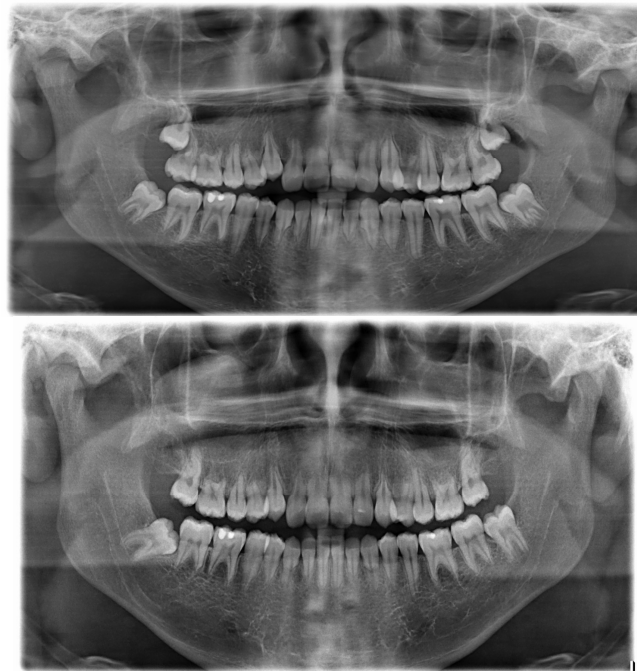


Fig. 4. Case B: Upper: Orthopantomogram from a male 15 years of age, who has never received orthodontic treatment. Observed severe resorption as well in molars, premolars and incisors. Also, note irregular bony contours of the cancellous bone. Lower: A follow up orthopantomogram from the male illustrated in the upper figure. At this present stage the male is 16 years and 3 months old. The second maxillary molars have been extracted due to resorption observed in the upper figure. Comparison of the two radiographs demonstrate severe aggravation of the resorption processes. Also, note in the lower orthopantomogram the irregularities of the cancellous bone contours

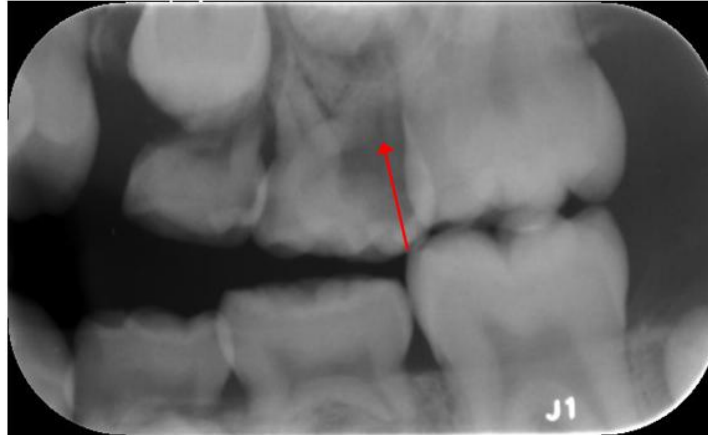

Fig. 5. Case B: This bitewing radiograph taken at the age of 7 years and 10 months from the male illustrated in Fig. 4. The radiograph was the only available radiograph of primary teeth in this individual. Note an abnormal resorption process in the maxillary second primary molar marked by a red arrow

2. METHODS

2.1 Serum Tests

In the search for literature focusing on conditions affecting as well teeth as bone tissue in clinically non-syndromic children, the first condition which appeared, was hypophosphatasia. Hypophosphatasia (HPP) is a heterogeneous rare inherited disorder of bone and mineral metabolism, first described by Rathbun in 1948 [5]. It is caused by various mutations in the ALPL gene (localized on chromosome 1p36. 1-34) encoding the tissue-nonspecific isoenzyme of alkaline phosphatase. Until now, more than 260 different disease-causing mutations have been reported in the ALPL gene mutations database [6]. HPP is traditionally divided in five different clinical types. Perinatal HPP, Infantile HPP, Juvenile HPP, Adult HPP, Odonto HPP [7]. Characteristic for HPP is that mild forms may present unspecific symptoms and be more frequent than previously assumed [7]. Adults with HPP may however present with low bone mass [7]. Acute hypophosphatasia is associated with profound illness, followed by increased short-term mortality [8]. Information on the different types indicate early loss of primary teeth in juvenile HPP and early loss of teeth in both dentitions in adult HPP. Whether the tooth loss was a result of root resorption or of periodontal diseases has never been described. Accordingly, the two patients, A and B, have had a serum test taken at two different laboratories and case A was also offered a genetic test, see below.

2.1.1 Serum analysis case A

Examined in a French laboratory October 2019. Among the different substances analysed, the patient demonstrated low vitamin D level, whereas phosphate, parathyroid hormone (PTH) and Calcium were within normal ranges. Alkaline phosphatase (ALP) was not determined in this laboratory. The vitamin D value was 35 nmol/l, and the normal reference intervals for vitamin D values in France were from 75 nmol/l (min) to 150 nmol/l (max).

2.1.2 Serum analysis case B

Examined in a Danish laboratory March 2020. Serum analysis revealed low values of D-vitamin and low values of ALP. PTH and calcium were within normal ranges. The vitamin D value was 35 nmol/l, and the normal reference intervals for vitamin D values in Denmark were from 50 nmol/l (min) to 160 nmol/l (max). The ALP value was 1.00 mmol/l and the normal reference intervals were 1.16 mmol/l (min) to 1.81 mmol/l (max).

2.2 Genetic Screening

Blood for genetic screening was received from Case A early 2020. Due to the Covid-19 pandemic the University Laboratory was more or less closed until Summer 2020. Whole Genome Exome sequencing (WES) was performed at a commercial laboratory (Dante labs). Resulting fastq files were aligned to a human reference genome (GRCh37) and variants were called using GATK pipeline following the Best Practices

workflow [9]. Filtering and prioritization of variants were done using VarSeq [10].

3. RESULTS

3.1 Results of Serum Tests

The common registered abnormality in both cases was a low D-vitamin level.

3.1.1 Comments to serum tests

A number of methodological considerations is necessary when evaluation of serum tests in patients with possible metabolic bone disease are performed. For example, assessment of results of calcium measurements is dependent of entity: total calcium, ionized calcium or albumen corrected calcium; PTH exists in different molecular forms; 25(OH)D (25 hydroxycholecalciferol, calcifediol) and is dependent on age, gender, ethnicity and season of the year, and serum phosphate depends on e.g. renal function. Furthermore, various medications are known to affect the tests, and intercurrent diseases, especially hormonal disturbances, may regulate bone metabolic markers [11-13]. In addition, dietary factors may affect especially calcium and phosphate. It is also important to know the exact methods used in the different commercial laboratories for analyses and sensitivity of the tests.

These considerations make it difficult to compare blood tests from different laboratories in an inhomogeneous group of persons, which is often the condition, when case studies from different countries are compared.

3.1.2 Results of genetic tests

Only one variant in the ALPL gene was identified, a homozygous synonymous variant T<C at position chr1:21889635 (hg19). The corresponding wild type AGT codon and the variant ACT codon are both translated into a Serine moiety. This variant known as rs1780316 is present in homozygous form in 13471 out of 126158 genomes in The Genome Aggregation Database (gnomAD) [14], and it is predicted to be benign. No other pathogenic variants, which could explain the phenotype, were revealed by WES.

3.1.3 Comments to genetic test

HPP is a genetically homogeneous disorder with only one known gene (ALPL) involved, and it has

been suggested that all patients with hypophosphatasia carry at least one mutation in ALPL [15]. Moreover, deletions of ALPL seems to be very rare [15] and DNA sequencing should be able to reveal the vast majority of ALPL mutations in HPP. Still, two out of 16 adults originating from a Spanish osteoporosis cohort with decreased ALP and increased PLP (Pyridoxal-5-prime-phosphate) levels had no ALPL mutations, suggesting that a genetic analysis may not be able to establish an HPP diagnosis in all cases [16].

As a conclusion, the genetic analysis of case A was considered negative, which strongly supports that case A was not a HPP case.

4. DISCUSSION

The aggressive resorptions observed in case A were not caused by the orthodontic treatment. The resorption changes appear in the primary as well as in the permanent dentitions.

From an etiological point of view it is interesting to observe that resorption processes occur in all teeth. This indicate a possible mesenchymal defect or an ectodermal defect [17]. Had it been a resorption defect caused by abnormal innervation, the resorption defect would have occurred in limited regions, so-called innervation fields [18]. Also, the interrelationship between resorption in the primary and permanent dentitions is an interesting find [19]. This supports the hypothesis regarding a general medical disease as a causative factor for the observed idiopathic root resorptions.

The following diagnosis, which includes lowered ALP and/or lowered D vitamin associated with dental affections may be considered.

Osteomalasia is most often caused by severe vitamin D deficiency and associated with lowered Calcium, phosphate, increased ALP and PTH.

Hypophosphatasia (HPP) including Odontohypophosphatasia is associated with lowered ALP, calcium, phosphate, lowered or normal 25(OH) D. and may eventually lead to rickets or Osteomalasia. However, a definitive diagnosis is dependent on genetic analysis as all clinical sub-types of hypophosphatasia have been traced to genetic mutations in the gene encoding TNSALP (tissue-nonspecific alkaline phosphatase), which is localized on chromosome 1p36.1-34 in humans.

Hypophosphatemic Vitamin D-Resistant Rickets (X linked) is associated with raised ALP, decreased calcium, phosphate, lowered or normal 25(OH) D.

Moreover, it is possible that the conditions could be a third, not previously biochemically described, type of idiopathic root resorption.

It is suggested that case A could have osteomalasia, which may be the late stage of hypophosphatasia. This case had lowered values of vitamin D concomitant with the presence of idiopathic root resorption. The genetic analysis strongly supported that case A did not suffer from HPP.

Case B may have hypophosphatasia based on low values of D-vitamin, phosphate and low values of ALP, with the presence of idiopathic root resorption, though the genetic proof is lacking.

An Idiopathic condition suggests that the cause behind the condition has not been known until now. It should also be considered that the cases presented cannot be compared uncritically to other published cases, as the literature does not normally include blood tests or genetic tests from patients with idiopathic root resorptions.

Questions: The question is if the aetiology behind resorptions and the changes in the pattern of the trabecular and cortical bone are related to the serum values and especially to the D-vitamin deficit. This is a question to solve in future studies.

Similarities between odontoclasts and osteoclasts have not been documented [20]. If idiopathic resorption by dentinoclast could be a sign also of abnormal osteoclast function, it would be important not only for the patient but also for future paediatric research.

This report may address several questions to pediatricians and endocrinologists:

- Is there an endocrinological treatment for D-vitamin deficit, which could affect the resorption process?
- Are there other medical or chemical analyses of importance to investigate in idiopathic resorption cases?
- How can the influence of calcium, acid and basic phosphatases be evaluated?

Guidance: For the clinician in odontology it is very important to diagnose cases with inborn tendency to idiopathic root-resorption. Some guidance can be given.

An advice is to be aware of the resorption pattern in the primary dentition before starting an orthodontic treatment. Also, the family disposition for resorption must be reported.

Finally, the 2 cases demonstrated that patterns of root resorption and bony contours might be interrelated. These hard tissue patterns should be mapped in the future. There is still the problem that standards for bony contours observed in the jaws do not exist.

This presentation represents a new field of research, which requires a systematic way of diagnosing. In case A, which was a severe case, it was decided to establish a serum analysis and a genetic analysis simultaneously. As the genetic analysis is costly, it would be recommended to await the results of the serum analysis before performing a genetic analysis. According to present insight, the serum analysis should in all cases include a systematic analysis for vitamin D, for basic phosphatase, for alkaline phosphatase (ALP) and also for calcium and phosphate. Moreover, normal standards for serum values in diseases with different mineralization defects should be available.

5. CONCLUSION

Two cases, A and B, with idiopathic resorptions are presented. Case A had received orthodontic treatment, case B had never received orthodontic treatment.

Cases A and B both had low values of vitamin D. In addition, case B had low value of alkaline phosphatase (ALP). Case A was genetically negative for hypophosphasia (HPP).

By retrospection, both cases revealed severe resorption in the primary dentition before onset of orthodontic treatment.

It was concluded that the resorptions observed in the permanent teeth in case A was not a consequence of the orthodontic treatment. It is suggested that case A could have osteomalasia, while case B may have HPP.

CONSENT

All authors declare that written informed consent was obtained from the patients for publication of this case report and accompanying images. A copy of the written consent is available for review by the Editorial Office/Chief Editor/Editorial Board of this journal.

ETHICAL APPROVAL

As per international standard or university standard written ethical approval has been collected and preserved by the author(s).

ACKNOWLEDGEMENT

Thank you to Drs Sophie Rozenzweig and Clément Da Silva and to departmental secretaries Linda Michelsen and Eva Reinwald.

COMPETING INTERESTS

Authors have declared that no competing interests exist.

REFERENCES

1. Kjaer I. Etiology-Based Dental and Craniofacial Diagnostics. Wiley-Blackwell; 2016.
2. Kjaer I. External root resorption - different aetiologies explained from the composition of the human root-close periodontal membrane. *Hypotheses* 2013;4(3):75-9.
3. Kjaer I, Nolting D. The human periodontal membrane - focusing on the spatial interrelation between the epithelial layer of Malassez, fibers and innervation. *Acta Odontol Scand* 2009;67(3):134-8.
4. Rathbun JC. Hypophosphatasie; a new developmental anomaly. *Am J Dis Child*; 1948;75(6):822-31.
5. Kjaer I. Morphological characteristics of dentitions developing excessive root resorption during orthodontic treatment. *Eur J Orthod*.1995;17(1):25-34.
6. Hofmann SC, Girschick HJ, Menstrup B, Graser S, et al. Clinical aspects of Hypophosphatasia: An Update. *Clin Rev Bone Min Metabol*. 2013;11(2):60-70.
7. Hepp N, Frederiksen AL, Khosravi J, Jensen JB. Diagnostics and treatment of hypophosphatasia. *Ugeskr Laeger* 2018;180(35):V10170736.
8. McKiernan FE, Shrestha LK, Berg RL, Fuehrer JT. Acute hypophosphatasemia. *Osteoporos Int* 2014;25(2):519-23.
9. Van der Auwera GA, Carneiro MO, Hartl C, Poplin R, et al. From FastQ data to high confidence variant calls: the genome analysis toolkit best practices pipeline. *Curr Protoc Bioinformatics* 2013;43(1110):11.10.1-11.10.33.
10. Available:<https://www.goldenhelix.com/products/VarSeq/>
11. Balbaied T, Moore E. Overview of optical and electrochemical alkaline phosphatase (ALP) biosensors: Recent approaches in cells culture techniques. *Biosensor (Basel)*. 2019;9(3):120.
12. Jakobsen J, Andersen EAW, Christensen T, Andersen R, Bügel S. Vitamin D vitamers affect vitamin D status differently in young healthy males. *Nutrients*. 2018;10(1):12-14.
13. Gannagé-Yared M-H, Younés N, Azzi A-S, Sleilaty G. Comparison between second- and third-generation PTH assays during minimally invasive parathyroidectomy (MIP). *Int J Endocrinol* 2020;(2020):5230985.
14. Available:<https://gnomad.broadinstitute.org/>
15. Whyte MP. Hypophosphatasia - aetiology, nosology, pathogenesis, diagnosis and treatment. *Nat Rev Endocrinol* 2016;12(4):233-46.
16. Alonso N, Larraz-Prieto B, Berg K, Lamber Z, et al. Loss-of-function mutations in the ALPL gene presenting with adult onset osteoporosis and low serum concentrations of tota. *J Bone Miner Res*. 2020;35(4):657-61.
17. Hansen IV, Vedtofte H, Kjaer I. Remember the periroot sheet in orthodontic treatment of ectodermal dysplasia patients. *Dental Hypotheses*. 2014;5(4):164-7.
18. Kjaer I, Strøm C, Worsaae N. Regional aggressive root resorption caused by neuronal virus infection. *Case Rep Dent* 2012;2012:693240.
19. Bille MLB, Kvetny MJ, Kjaer I. A possible association between early apical resorption of primary teeth and ectodermal characteristics of the permanent dentition. *Eur J Orthod*. 2008;30(4):346-51.

20. Wang Z, McCauley LK. Osteoclasts and development and disease. Oral Dis. odontoclasts: Signaling pathways to 2011;17(2):129-42.

© 2021 Kjaer et al.; This is an Open Access article distributed under the terms of the Creative Commons Attribution License (<http://creativecommons.org/licenses/by/4.0>), which permits unrestricted use, distribution, and reproduction in any medium, provided the original work is properly cited.

Peer-review history:
The peer review history for this paper can be accessed here:
<http://www.sdiarticle4.com/review-history/66429>